

51

EXAMINATION PROTOCOL

2022-10791  
BRIGNOLE, DOUGLAS PAUL

Page 1 of 2

The body is identified by medical examiner toe tags and ankle band.

The body

is clothed  
 was not clothed

and I

inspected the clothing.  
 did not see the clothing.

Rigor and livor are altered.

Appears:  Asian  Black  Caucasian  Hispanic  Indian

Sex:  Male  Female. Appears the stated age of: 62 years

The body weighs approximately 185 pounds, measures approximately 68 inches and is

well-nourished and appropriately developed for age.

Embalmed:  No  Yes

Irides:  Blue  Brown  Green

Sclera:  Normal  Icteric  Congested without petechial hemorrhages

Conjunctival Petechial Hemorrhage:  No  Yes

Head Hair:  Gray and short in length

Facial hair:  Absent  Present, stubble

Teeth:  Absent  Present

Dentures:  Absent  Present

Scars:  None identified  Present

Tattoos:  None identified  Present

EVIDENCE OF THERAPEUTIC INTERVENTION:

There is no evidence of recent therapeutic intervention.

The chest has no increased anterior-posterior diameter. The extremities are well-developed and symmetrical.

The abdomen is

flat.

The genitalia are those of an adult

female.  
 male.

**EXAMINATION PROTOCOL****2022-10791**

page 2 of 2

**EVIDENCE OF INJURY:**

A small tan-brown abrasion involves the left forehead. Scattered abrasions involve the feet.

Exam photographs	<input type="checkbox"/> Yes	<input checked="" type="checkbox"/> No	Fluoroscopy	<input type="checkbox"/> Yes	<input checked="" type="checkbox"/> No
X-Rays	<input type="checkbox"/> Yes	<input checked="" type="checkbox"/> No	Cultures	<input type="checkbox"/> Yes	<input checked="" type="checkbox"/> No
Toxicology	<input checked="" type="checkbox"/> Yes	<input type="checkbox"/> No	Cassettes	<input type="checkbox"/> Yes	<input checked="" type="checkbox"/> No
GSR	<input type="checkbox"/> Yes	<input checked="" type="checkbox"/> No	Evidence	<input type="checkbox"/> Yes	<input checked="" type="checkbox"/> No

A nasopharyngeal swab for common viral pathogens is positive for SARS-CoV-2.

Indicate other form number(s) attached: #20

**PATHOLOGIC DIAGNOSES**

- I. Complications of COVID-19 infection
  - A. Nasopharyngeal swab positive for SARS-CoV-2 (COVID-19)
- II. Atherosclerotic cardiovascular disease
  - A. Hyperlipidemia, reported
  - B. Unspecified cardiac disease, reported
- III. Blunt trauma, minor
  - A. Abrasion, forehead
  - B. Abrasions, feet

**SUMMARY AND OPINION**

Douglas Brignole was a 62-year-old man with reported medical history of hyperlipidemia, hypogonadism, and unspecified cardiac disease.

According to the Medical Examiner Investigator's report, Mr. Brignole was found unresponsive on the ground in his home. Emergency medical services were contacted, and he was pronounced deceased. He was reportedly feeling unwell recently.

External examination revealed a well-developed man without trauma to explain death. Small scrapes involved his forehead and feet.

Toxicology testing will not be performed. A nasopharyngeal swab for common respiratory viruses was positive for SARS-CoV-2 (COVID-19).

Mr. Brignole was positive for infection with the novel coronavirus, which is the cause of COVID-19. COVID-19 can result in a spectrum of immune responses that range from asymptomatic and mild, to severe respiratory symptoms and death in susceptible individuals. Inflammation and fluid-buildup in the lungs (in response to the infection) prevents the lungs from being able to adequately exchange oxygen with the environment. When severe, organ damage and organ failure from lack of oxygen can occur, which can cause death. Mr. Brignole's underlying medical conditions, including heart disease from atherosclerosis would have made him less able to tolerate the effects of COVID-19, contributing to death.

Given the available investigative information and exam, it is my opinion that the cause and manner of death are best certified as:

CAUSE OF DEATH: COVID-19 INFECTION

CONTRIBUTING FACTOR: ATHEROSCLEROTIC CARDIOVASCULAR DISEASE

MANNER OF DEATH: NATURAL



Michael Harrell, M.D.  
Deputy Medical Examiner

10-21-2022

Date

15

AUTOPSY CLASS:  A  B  C  Examination Only D

FAMILY OBJECTION TO AUTOPSY

Date: 10/14 Time: 8:50 Dr. Michael Herrell

FINAL ON: 10/21/2022 By: Michael Herrell (Print)

APPROXIMATE INTERVAL BETWEEN ONSET AND DEATH

2022-10791

BRIGNOLE, DOUGLAS

NAT

314

DEATH WAS CAUSED BY: (Enter only one cause per line for A, B, C, and D)

IMMEDIATE CAUSE:

(A) Covid-19 infection

DUE TO, OR AS A CONSEQUENCE OF:

(B)

DUE TO, OR AS A CONSEQUENCE OF:

(C)

DUE TO, OR AS A CONSEQUENCE OF:

(D)

OTHER CONDITIONS CONTRIBUTING BUT NOT RELATED TO THE IMMEDIATE CAUSE OF DEATH:

Atherosclerotic Cardiovascular disease

NATURAL  SUICIDE  HOMICIDE

ACCIDENT  COULD NOT BE DETERMINED

If other than natural causes, HOW DID INJURY OCCUR?

WAS OPERATION PERFORMED FOR ANY CONDITION STATED ABOVE:  YES  NO

TYPE OF SURGERY: \_\_\_\_\_ DATE: \_\_\_\_\_

ORGAN PROCUREMENT  TECHNICIAN: Flores

PREGNANCY IN LAST YEAR  YES  NO  UNK  NOT APPLICABLE

WITNESS TO AUTOPSY  EVIDENCE RECOVERED AT AUTOPSY  
Item Description:

62 yom, recent illness,  
⊖ illicit@ home  
held tox, pending  
NP-swabs

Age: 62 Gender:  Male  Female

PRIOR EXAMINATION REVIEW BY DME

BODY TAG  CLOTHING  
 X-RAY (No. \_\_\_\_\_)  FLUORO  
 SPECIAL PROCESSING TAG  MED. RECORDS  
 AT SCENE PHOTOS (No. \_\_\_\_\_)

CASE CIRCUMSTANCES

EMBALMED  
 DECOMPOSED  
 >24 HRS IN HOSPITAL  
 OTHER: \_\_\_\_\_ (Reason)

TYPING SPECIMEN

TYPING SPECIMEN TAKEN BY: Herrell

SOURCE: Jailer

TOXICOLOGY SPECIMEN

COLLECTED BY: Herrell  
 HEART BLOOD  STOMACH CONTENTS  
 FEMORAL BLOOD  VITREOUS

TECHNIQUE: East  
 BLOOD  SPLEEN  
 BLOOD  KIDNEY  
 BILE  \_\_\_\_\_  
 LIVER  \_\_\_\_\_  
 URINE  \_\_\_\_\_

URINE GLUCOSE DIPSTICK RESULT: 4+ 3+ 2+ 1+ 0

TOX SPECIMEN RECONCILIATION BY: ecf

HISTOLOGY

Regular (No. \_\_\_\_\_)  Oversize (No. \_\_\_\_\_)  
Histopath Cut:  Autopsy  Lab

TOXICOLOGY REQUESTS

FORM 3A:  YES  NO  
 NO TOXICOLOGY REQUESTED  
SCREEN  C  H  T  S  D  
 ALCOHOL ONLY  
 CARBON MONOXIDE  
 OTHER (Specify drug and tissue)

REQUESTED MATERIAL ON PENDING CASES

POLICE REPORT  MED HISTORY  
 TOX FOR COD  HISTOLOGY  
 TOX FOR R/O  INVESTIGATIONS  
 MICROBIOLOGY - viral  EYE PATH. CONS.  
 RADIOLOGY CONS.  
 CONSULT ON: \_\_\_\_\_  
 BRAIN SUBMITTED  
 NEURO CONSULT  DME TO CUT  
 CRIMINALISTICS  
 GSR  SEXUAL ASSAULT  OTHER

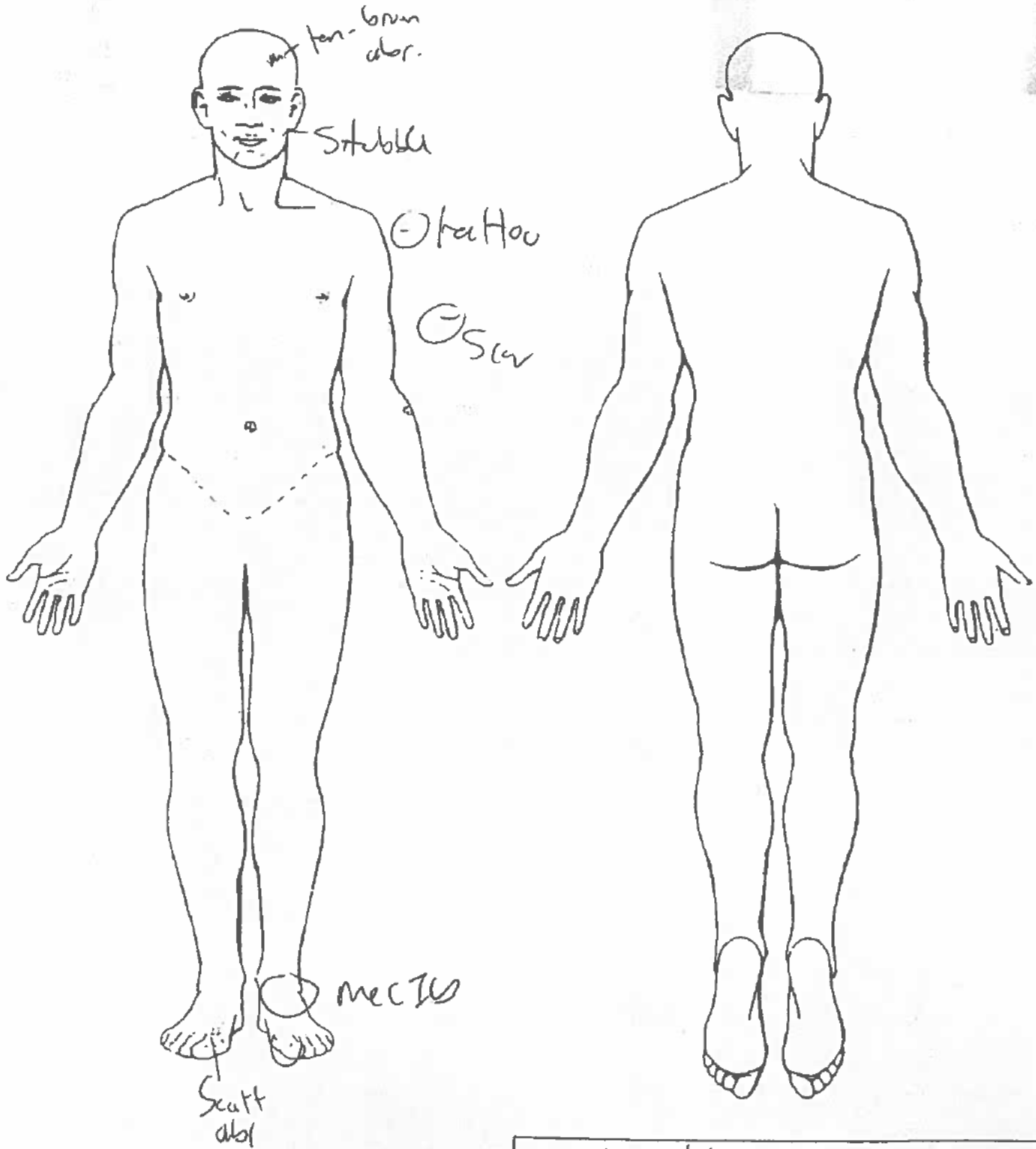
RESIDENT

DME


20

hair: Short Gray, stubble  
eyes: hazel lens  
teeth: not used

2022-10791  
BRIGNOLE, DOUGLAS  
NAT 314



Date 10/14/22

  
Deputy Medical Examiner M.D.

D Hamell

COUNTY OF LOS ANGELES

CASE REPORT

DEPARTMENT OF CORONER

1	APPARENT MODE <b>NATURAL</b>	CASE NO <b>2022-10791</b>
	SPECIAL CIRCUMSTANCES	CRYPT <b>314</b>

LAST, FIRST MIDDLE **BRIGNOLE, DOUGLAS PAUL** AKA #

ADDRESS **1421 S. SHERBOURNE DRIVE** CITY **LOS ANGELES** STATE **CA** ZIP **90035**

SEX MALE	RACE APPEARS CAUCASIAN	DOB 12/15/1959	AGE 62	HGT 68 in.	WGT 185 lbs.	EYES BROWN	HAIR BROWN	TEETH ALL NATURAL TEETH	FACIAL HAIR UNSHAVEN	ID VIEW Yes	CONDITION FAIR
-------------	---------------------------	-------------------	-----------	---------------	-----------------	---------------	---------------	----------------------------	-------------------------	----------------	-------------------

MARK TYPE	MARK LOCATION	MARK DESCRIPTION

ID METHOD  
**FINGERPRINTS FROM DOJ**

IDENTIFIED BY NAME (PRINT)	RELATIONSHIP	PHONE	DATE	TIME
<b>DOJ, FBI, LASD FINGERPRINTS</b>			<b>10/13/2022</b>	<b>16:48</b>

PLACE OF DEATH / PLACE FOUND	ADDRESS OR LOCATION	CITY	ZIP
<b>RESIDENCE</b>	<b>1421 S. SHERBOURNE DRIVE</b>	<b>LOS ANGELES</b>	<b>90035</b>

PLACE OF INJURY	AT WORK	DATE	TIME	LOCATION OR ADDRESS	ZIP
	No				

DOD <b>10/13/2022</b>	TIME <b>09:25</b>	FOUND OR PRONOUNCED BY <b>LAFD RA 58, MATCHENEY</b>
--------------------------	----------------------	--

OTHER AGENCY INV. OFFICER <b>LAPD WEST LOS ANGELES - REZEKALLA &amp; GLAN</b>	PHONE <b>(310) 440-0701</b>	REPORT NO. <b>22101300001306</b>	NOTIFIED BY <b>NO</b>
--	--------------------------------	-------------------------------------	--------------------------

TRANSPORTED BY	TO <b>LOS ANGELES FSC</b>	DATE	TIME
----------------	------------------------------	------	------

FINGERPRINTS?	No	CLOTHING	Yes	PARPT	No	MORTUARY	
MED. EV.	No	INVEST. PHOTO #	52	SEAL TYPE	<b>CORONER SEAL</b>	HOSP RPT	No
PHYS. EV.	No	EVIDENCE LOG	No	PROPERTY?	Yes	HOSP CHART	No
SUICIDE NOTE	No	GSR NO		RCPT. NO.	<b>338596</b>	PF NO.	

SYNOPSIS  
 +FORM 1 ONLY+ ACCORDING TO THE REPORTED INFORMATION, ON 10/13/22 AROUND 0900 HOURS, THE DECEDENT'S HOUSEKEEPER WENT TO THE DECEDENT'S APARTMENT FOR A SCHEDULED APPOINTMENT. SHE ENTERED THE HOME AND FOUND THE DECEDENT LYING PRONE ON THE FLOOR UNRESPONSIVE AND CALLED 911. SHE ALSO WENT TO GET THE DECEDENT'S NEIGHBOR FOR HELP. PER THE 911 OPERATOR, THE HOUSEKEEPER AND THE DECEDENT'S NEIGHBOR TURNED THE DECEDENT ONTO HIS BACK. LAFD RA 58 THEN RESPONDED AND PARAMEDIC MATCHENEY PRONOUNCED DEATH AT 0925 HOURS WITH NO MEDICAL INTERVENTION. THE DECEDENT WAS LAST SEEN ALIVE ON 10/10/22 BY A NEIGHBOR. PER THE DECEDENT'S DOCTOR, HE HAD A HISTORY OF HYPERLIPIDEMIA, ADD, HYPOGONADISM, AND UNSPECIFIED CARDIAC ISSUES. IT IS BELIEVED HE LAST SAW HIS DOCTOR WITHIN THE PAST 6 MONTHS. FAMILY REPORTED THE DECEDENT HAD NO HISTORY OF ALCOHOL ABUSE OR ILLICIT DRUG USE. PER A FRIEND, THE DECEDENT WAS A COMPETITIVE BODY BUILDER AND WAS KNOWN TO USE STEROIDS OCCASIONALLY. THE FRIEND ALSO MENTIONED THE DECEDENT HAD RECENTLY TRAVELLED TO ATLANTIC CITY FOR A COMPETITION AND BECAME SICK WITH A FLU AROUND 10/8/22. MULTIPLE PACKS OF OVER THE COUNTER COLD/FLU MEDICATIONS WERE FOUND ON SCENE. AN EXTERNAL EXAMINATION OF THE DECEDENT ON SCENE REVEALED NO OBVIOUS SIGNS OF TRUAMA. ANT ACTIVITY WAS OBSERVED TO HIS FACE. HE WAS ALSO NOTED TO BE INCONTINENT. FOUL PLAY IS NOT SUSPECTED.

JUSTINE EPPERSON 643074		INVESTIGATOR	DATE 10/13/2022	REVIEWED BY  A. EARL	DATE 10/13/22	TIME 2042
----------------------------	---	--------------	--------------------	--	------------------	--------------

FORM #3 NARRATIVE TO FOLLOW?