

6

Georges Herzog

Preface

Every minute somewhere in the world a child is born with one of the many forms of facial clefts. In South America a new baby with a cleft is born every half hour; in Europe it is one baby per hour. Each year almost 5000 families in the USA experience the birth of a baby with a facial cleft. Every time, the parents suffer anguish: traumatised, overwhelmed by a malformation that cannot be hidden. The malformation spoils the joy that the much awaited birth should have given.

Can the new parents and their baby find a way to smile?

Could the problem have been foreseen? Or prevented?

What does the future hold? How can one repair the consequences of this embryological accident?

What will be the quality of life for this little child?

So many questions...

In the USA statistics show that each year 150,000 babies are born with a congenital malformation. That represents one baby in 28! We might suppose that Europe has a similar incidence. Among the thousands of known malformations we only know the origin or cause of a small percentage. Genetics and the environment play a determining role, sometimes the one or the other, sometimes both together.

From conception to birth numerous problems and accidents at all stages of development can cause the death of the embryo or foetus. The worst malformations are incompatible with life, and occur in the first weeks, and so involve the embryo. The most frequent congenital malformations concern the heart, the central nervous system, the urogenital system and the limbs. Some of them leave serious functional sequelae, which affect the quality of life. One may think of cardiac and central nervous malformations (*cerebral palsy*, *spina bifida*). Facial clefts are the commonest congenital facial malformations. Their consequences are many and varied, both in number and seriousness. They require the intervention of many specialists and demand long-term care, but they do not threaten the baby's life and an entirely normal quality of life is possible in the great majority of cases.

A facial cleft affects the baby's entourage because it is visible. It is aggressive in its visibility and is compounded by the brutality of its common name: harelip. This term is so shocking, by its cruelty and unworthiness, that it should be abandoned. It is unworthy of the little human being who is suffering from it, the victim of an embryological accident for which no one, neither parents nor even less the baby himself, can be held responsible. The baby and his or her parents deserve respect and support.

The general public should be better informed. Ignorance and superstition have for too long added to the families' pain when one or more members have been affected by this condition. This is no curse: just an embryological accident of which the causes are not yet fully known and of which the more or less severe sequelae can now be treated very effectively, corrected and even eliminated.

The sequelae of facial clefts are many and involve many tissues, organs and systems: from an aesthetic point of view, the lips and nose. From a functional point of view feeding, breathing and speaking. And also the personality, the psychological well-being and sometimes social integration. The treatment of these multiple sequelae must therefore be multidisciplinary, in the hands of a team composed of specialists from different fields working together to offer the best care, according to the priorities, needs and requests of the patient and his parents. This need for a multidisciplinary approach has been overwhelmingly endorsed, and its efficacy is today universally accepted. But this team must have a high level of experience and competence. These two qualities can only be acquired by centralisation and rigorous organisation. In order to maintain a high level of competence a multidisciplinary team must follow a large number of patients, for not only are sequelae numerous but also very variable according to the type of cleft and its seriousness. A team which can only follow a few new cases each year unfortunately cannot claim to offer the most efficient care.

An assessment of methods of care was made by the Eurocleft¹ Project from 1996 to 2000. This project involved some 30 countries and aimed at identifying multidisciplinary centres, recording their different methods of treatment and trying to reach a consensus about methods to improve the overall quality of care. This European programme enabled the establishment of certain fundamental principles that should be respected. On the other hand, it was not part of its remit to decide which technique or surgical operation gave the best results. This question remains wide open and has been the subject of controversy for decades. An international study of unprecedented scope (Ross 1987²) attempted to analyse the different factors which could affect craniofacial growth in individuals with complete unilateral cleft lip and palate, but could not draw definitive conclusions. Nevertheless this study did establish that surgical technique, which varies greatly between the hundreds of specialised care centres in Europe and around the world, is not in itself the determining element. The competence and experience of the surgeons have a much more important influence on the aesthetic and functional results in the long term. The Eurocleft Project, with the comparisons between different centres that it was able to undertake, enabled us to distinguish a number of factors that are of interest to mention here.

The United Kingdom, with a population of 59.1 million and an incidence of 1172 facial clefts per year had, in 1998, 57 centres where patients were treated by a multidisciplinary team. A third of the surgeons in these centres carried out less than five operations per year, whereas six surgeons operated on more than 30 new patients each year. It was realised that in those centres where too few patients were seen, the number of operations carried out was relatively much too large. This suggests that teams and, particularly, surgeons who see too few new patients (*less than 20 to 30 per year*) do not have enough “routine” to obtain optimal results. In consequence children and adolescents followed by these teams and operated on by these surgeons may keep cosmetic and functional sequelae, and need multiple operations which in the end do not give satisfactory results.

With this evidence, the country’s health authorities decided to centralise, and limit the number of centres to eight to 15, each with two surgeons operating on 40 to 50 new cases per year each. This is progress for the patients who undergo fewer operations. The state also benefits, because fewer operations mean less costs for improved efficacy.

The quality of the overall results by the numerous small teams operating in the United Kingdom before the restructuring was unfortunately among the worst in Europe.

In Norway, with 4.4 million inhabitants there are, all in all, only two multidisciplinary teams to treat the 100 to 150 patients each year. The quality of their results is recognised as among the best in the world (*see Eurocleft¹; Ross 1987²; Shaw et al 1992³ in References section*)

In Switzerland for a population of 7.2 million and 80 to 120 new cases per year there are 10 multidisciplinary teams, only two of which are active in Bern. The largest centres are affiliated to university hospitals and treat most cases. Those in Lausanne, Bern and Zurich each treat a mean of 25 to 30 new cases per year. All the other patients are treated by the other seven centres. If we deduct the 75 to 90 cases treated in Lausanne, Bern and Zurich, some 5 to 30 new cases per year are treated by these seven centres, which means i.e. between 0 and 5 patients per centre per year. This number is much too small to ensure a high level of care.

Progress in surgery in the last 50 years has been fantastic. The decrease in risk related to general anaesthesia, which the baby must have during the first few months of life, has been radical. In the same way, major progress in ENT (*ear, nose and throat*) treatment and speech therapy has brought a noticeable improvement in the quality of life of our patients, who hear and speak better. Orthodontics, partly thanks to modern maxillofacial surgical techniques, allows us to envisage solutions to the most complex problems and usually offers the patient complete cosmetic and functional rehabilitation. However, the competence and performance of the multidisciplinary team must also be of the highest quality at the purely human level.

It is precisely at this human level that technology has produced one of the most spectacular and valuable advances: antenatal ultrasound diagnosis. Investigative intrauterine imaging is marked by constant progress and refinement.

Today it allows an antenatal diagnosis in numerous cases of cleft lip and palate. It enables many future parents to better prepare themselves to affront and accept the facial malformation of the baby they are expecting.

This diagnosis, although not minimising the severity of the malformation, allows the radiologist and, very soon after, the multidisciplinary team to contact the future parents to offer them information and support. Important and valuable psychological aid can thus be provided before the birth. The malformation can be explained, its various forms illustrated and, above all, the possibilities for repair can be demonstrated, using notably “before and after” photographs. A dialogue can be set up between a representative of the team and the parents. Confidence can be built thanks to this dialogue and the team’s ready availability.

The parents know that they have a contact from then on, with whom they can discuss their problems and from whom they can obtain information and answers. On the day of birth, when they finally see their child, they will be better equipped to accept reality and bear their sorrow, for they will be prepared. Of course the worries and uncertainties for the future of their child will remain real, but part of the shock will have been countered. The agony of the brutal discovery of a malformation for which they were not prepared will have been spared them. Antenatal diagnosis, although not infallible, and not possible in all cases, represents a very appreciable advance for future parents.

For the members of the multidisciplinary team and for the parents and their child this diagnosis is the beginning of a long road, often difficult and sometimes painful. May this book contribute to better lighting that road, making it less chaotic and perhaps a little more serene.

The multi- disciplinary team

Introduction

Facial clefts, either of the lip or palate in isolation, or extending from the lips to the palate (Fig. 1) represent one of the commonest congenital malformations.

The fact that this malformation is so common in no way diminishes its impact in the eyes of the parents. They will consider their child with legitimate apprehension and fear for his or her development and the future consequences, or sequelae, which their condition could have in cosmetic and functional terms. The aim of this book

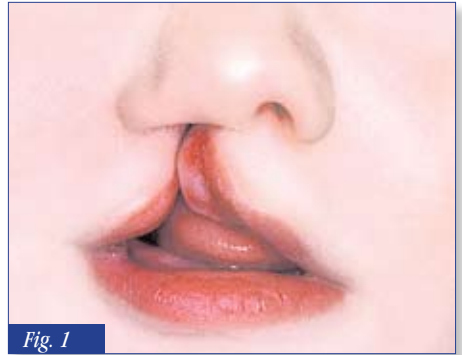

Fig. 1

One baby in 500 to 700 is born with cleft lip and/or palate

is to present the concept of the multidisciplinary facial cleft team, and summarise its functions by outlining its involvement in the care of children and adolescents with a facial cleft. It also attempts to tackle, as fully as possible without claiming to be exhaustive, some of the problems this congenital malformation might cause and the sequelae it might have.

The objective of the multidisciplinary team is to bring together specialists in rehabilitation of patients with this type of malformation in order to optimise the care they can administer. But before beginning its work, the team has a duty to inform parents, completely, individually and, above all, comprehensibly.

Only a multidisciplinary team can be fully efficient in helping parents and their child and in offering optimal care as a function of priorities (*objective*) and demands (*subjective*). Such a team must integrate specialists of all medical and paramedical disciplines which might be involved in the sequelae of clefts some time during the development of the baby, the young child, the adolescent and finally the young adult.

At birth, the baby is placed in the hands of the paediatric surgeon and orthodontist of the team. The first necessity is information, which can be direct and personal or written, as in this book. Further, with the extraordinary development of the Internet, extensive and promising possibilities are available to all who seek information.

The baby may very soon develop feeding problems, and frequently we have to provide him with a feeding plate (*Fig. 2 and 4*) which helps the baby feed during his first months and can be useful until the palate and lip are closed surgically. These surgical operations must be programmed individually according to a strict timetable. Later the child must be followed, like all children, by a paediatrician, but also by the multidisciplinary team, for his condition and the sequelae of his malformation require the assistance of trained and experienced specialists. On page 10 a table presents a multidisciplinary organisation of treatment with the various actions an affected child might need.

The function of the team is at two levels: an organ of general consultation, with regular meetings, and a specifically therapeutic function of treatment and care by the various practitioners. The advantages of team work are many, both for the patient and his entourage, especially his parents, as well as for the various specialists involved.

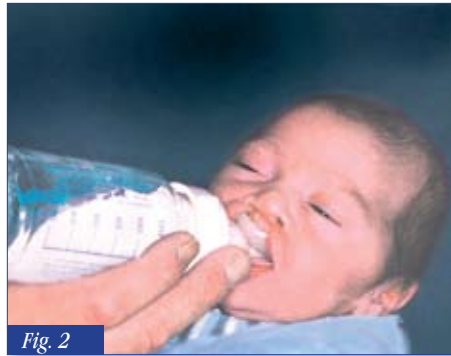

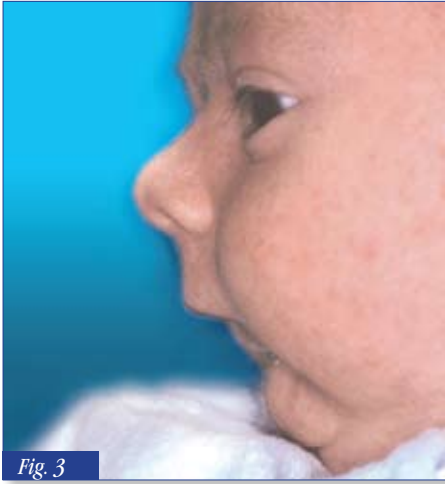
Fig. 2

After fitting a feeding plate the baby can easily be fed by bottle

Facial clefts present great variability. Variability in form of the cleft at the time of birth is logically associated with great diversity of sequelae they can have on the anatomy, development, aesthetics and function of the dental and the whole craniofacial complex. This variability is illustrated in Chapter 2.

The baby's feeding and breathing

The vital functions of feeding and breathing must have highest priority. A facial cleft can make sucking, and therefore feeding, difficult, whether at the breast or by bottle. With a cleft lip and palate it is virtually impossible to ensure a milk-tight seal because of the communication between the mouth and nose (*buccal and nasal cavities*). The baby cannot produce the necessary suction to feed on the maternal breast or from his bottle. Breathing can be disturbed especially in children with the anomaly known as Pierre Robin Sequence, a congenital condition combining micrognathia (*a small jaw*), glossoptosis (*the tongue is placed too far back*), and cleft palate (*Fig. 3*). In these babies the tongue can block the upper airways in the oropharynx (*the part of the combined food and air passage in the back of the mouth*) and so interfere with respiration.

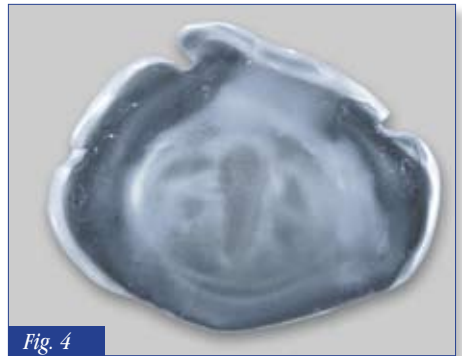


Micrognathia in Pierre Robin Sequence

The paediatric surgeon is the first to contact the parents, sometimes even before the birth if an antenatal ultrasound diagnosis has been made. From the first week of life the surgeon and the orthodontist discuss the need to construct a palatal plate (*also called a feeding plate*) in the case of potential or real problems of feeding or breathing by the baby. A palatal plate implies the making of an impression by the orthodontist, usually at the hospital as soon as possible after birth.

The palatal plate (*Fig. 4*) is made of acrylic resin, with the outer part rigid and the inner layer, which is in contact with the mucosa, softer and more flexible. It is perfectly shaped to the palate, and the baby adapts to it in a few hours, or days at most. The palatal plate makes feeding easier, for it seals off the communication between mouth and nose. The baby can produce good suction and so feed on milk almost normally.

The first surgical operation for the baby is to close a cleft in the soft palate, at around three to four months of age. The sutures used in this surgery are, as can be imagined, very delicate and relatively fragile. The feeding plate plays an important role in protecting these sutures against damage from outside, such as from a dummy, fingers, bottle or toys. After the second surgical operation, to close the hard palate and lip, the plate is no longer necessary. Meetings with the team members become less frequent, as less treatment is required for some time. After this primary surgery, routine checks by the paediatrician, the surgeon, the orthodontist and an ENT (*ear nose and throat*) specialist are organised.



Palatal or "feeding" plate

At around three years of age a first major check-up is necessary. It takes the form of a multidisciplinary meeting with the whole team present to examine the child, agree on his needs and plan further active treatment if it is needed.

At this age, the priority is not yet orthodontic. The deciduous (*or "milk"*) teeth are still present. The team observes the situation and discusses real or potential problems and gives advice, particularly concerning oral hygiene. The priority is speech and language therapy. The child is almost at school age, and a facial cleft may be associated with problems in acquiring and developing lan-

guage. Often a degree of hypernasality (*a nasal quality to the speech*) is present. The soft palate, responsible for the physiological closing of the posterior air passages may not be able to assume this function when the patient tries to make certain sounds. If too much air escapes through the nose the sounds are audibly different: hypernasality, or nasal voice.

The soft palate, although repaired at the age of three months using a relatively atraumatic surgical technique with attention being paid to reconstructing a near-normal musculature, may have limited movement due to light scarring. This can be compensated for either naturally or with the help of speech therapy. This is an absolute priority at preschool age for obvious reasons of social integration of the child. Usually speech and language therapy result in a noticeable reduction, or even elimination, of hypernasality.

In some unfortunately resistant cases, a surgical operation, velopharyngoplasty, might be envisaged. It consists of making a mucosal process between the soft palate and the back of the pharynx, so anatomically reducing the airflow expelled when making sounds. Various alternatives can be discussed at multidisciplinary meetings. The team's speech therapist attends these meetings and can decide on the therapeutic indications of each individual child.

ENT (*ear, nose and throat*)

Facial clefts affect the ENT domain in various ways and at various levels. Deviations of the nasal septum are often encountered and are sometimes quite large, affecting breathing. There is an increased risk of otitis media (*inflammation of the middle ear*). Any loss of auditory acuity in early childhood can have negative consequences for the development and acquisition of language. For these reasons regular checks by the team's ENT specialist, who is also specialised in audiophonology, are of the utmost importance.

Psychology

Psychological problems linked to the physical sequelae of the malformation may arise at any time during the development of the infant and the adolescent. Difficulties of integration are rather rare but are acutely felt and must be listened to attentively and answered by specialised counselling. The parents may need support and psychological counselling in order to overcome the difficulties related to their child's condition. The team's psychologist, specialised in the problems of childhood and adolescence, can provide an attentive ear: parents and children alike may need to have access to psychological counselling and therapy at all times.

In the end, these multidisciplinary meetings are above all an occasion for a periodic check on the health of the child and a way of following many different aspects of his development. For the parents they offer the possibility of expressing their wishes, of asking questions and of receiving advice on a wide range of subjects, all at an individual level and as completely and directly as possible. They enable them to meet all the people liable to be called upon to help their child or provide assistance in tackling various difficulties, either physical or psychological.

Timing of patient care proposed by the multidisciplinary cleft palate team CHUV, Lausanne, Switzerland

When?	What?	Who?
Birth	First contact and information Fitting of feeding plate	Paediatric surgeon Orthodontist
3 months	Surgical closure of soft palate	Paediatric surgeon
4-6 months	New feeding plate if necessary Surgical closure of hard palate and lip	Orthodontist Paediatric surgeon
8 months	Surgical closure of second lip in bilateral cleft	Paediatric surgeon
18 months- 3 years	Routine assessment	Paediatric surgeon, paediatrician, orthodontist, ENT specialist
3 years	First multidisciplinary meeting Speech and language therapy, if needed	Whole team
6 et 9 years	Second and third multidisciplinary meetings Dental and orthodontic assessment	Whole team
9-10 years	Alveolar bone graft Orthodontic treatment if required (<i>expansion of the upper dental arch</i>)	Maxillofacial surgeon Orthodontist
12 years	Fourth multidisciplinary meeting	Whole team
12-18 years	Orthodontic treatment (<i>variable length</i>) Fifth multidisciplinary meeting, if needed	Orthodontist Whole team
18-20 years	Last multidisciplinary meeting	Whole team

NB: the ages of the different sessions are approximate and can vary a little according to the child's individual needs.

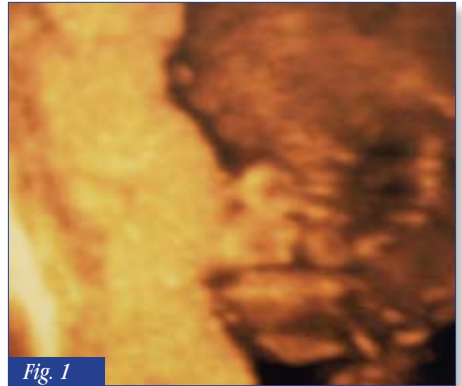Cleft lip and palate

Chapter 1

Once known as “barelip”, cleft lip, with or without associated cleft palate, remains a very common congenital malformation. Even if we have now, thankfully, abandoned the ugly term of barelip, this malformation nevertheless remains a painful experience for children and parents, notably at the psychological level.

A congenital malformation is not necessarily hereditary, even if genetics plays an important role in the etiology of facial cleft. Congenital means that the problem is present at birth. It does not imply a specific cause of the anomaly. Indeed, the causes of facial clefts are not fully understood and there is active research in the field.

It is sometimes possible to diagnose a facial cleft before birth by antenatal ultrasound during the second trimester of pregnancy (*Fig. 1*).



Antenatal diagnosis: cleft of the lip visible by ultrasound

This enables parents to be informed and thus avoid at least part of the emotional and psychological shock provoked by a diagnosis at the time of birth of their baby. We discussed in the Introduction that a broad multidisciplinary care plan is the only efficient method for treatment of all the sequelae of this congenital condition. This multidisciplinary approach must be continuous and intensive during the whole development and growth of the patient.

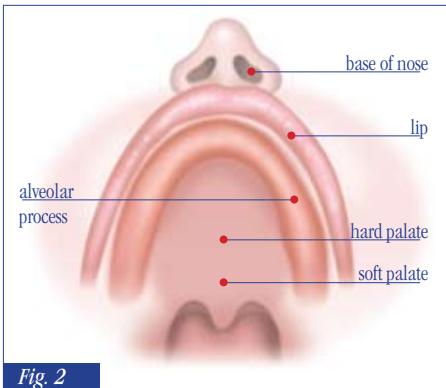


Fig. 2

Normal anatomy

This chapter describes in detail the different types of these malformations and the mechanisms of their development in the foetus. We shall briefly discuss their causes, although they are not all fully understood. We shall also consider epidemiological aspects, such as the frequency of occurrence of this condition, and the probability that it will reappear in a family of which a member already suffers from a facial cleft.

A little terminology to begin with:

Embryology

- *How does a cleft develop in the foetus?*
- *What are the different forms of facial clefts we might encounter?*

Etiology

- *What are the causes?*

Epidemiology

- *How frequently do these malformations occur in the population?*

Heredity

- *What are the risks of occurrence in a current pregnancy?*
- *What are the risks of recurrence in a future pregnancy?*

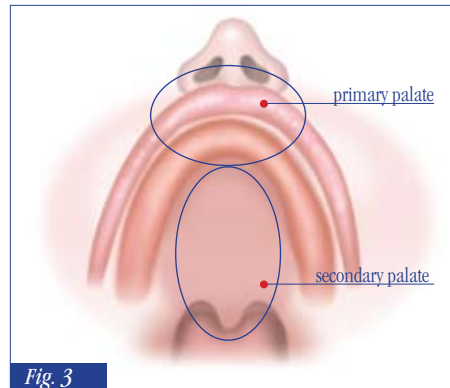


Fig. 3

Embryological concepts used to classify facial cleft

Embryology

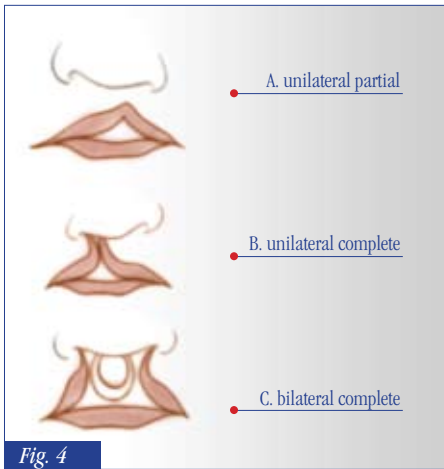
Embryology is the study of the development of the embryo and then of the foetus. The embryonic period spans from conception to the eighth week, after which we speak no more of an embryo but of a foetus. After the eighth week the principle tissues, organs and anatomical systems of the future baby are formed. They continue their development and growth beyond the eighth week, but from this time we can say that “everything is there”. Before describing the mechanisms leading to a facial cleft it is important to define a few terms and anatomical structures to make later descriptions easier to follow. Fig. 2 shows the normal anatomy of the palate, upper jaw and lip. We can consider this region in two parts (Fig. 3).

Primary palate

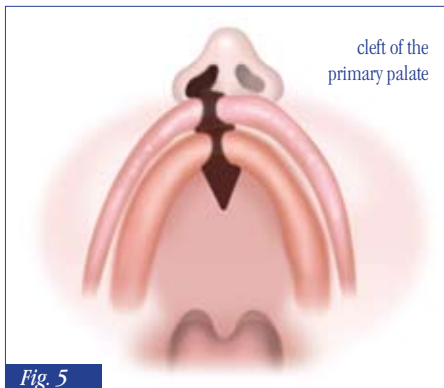
This is the region of the upper lip and the **alveolar process**, the part of the gum region of the upper jaw (*maxilla*) which carries the teeth. The primary palate forms first, already around the seventh week of intra-uterine life.

Clefts of the primary palate

- *partial cleft lip (Fig. 4A)*
- *complete cleft lip (Fig. 4B and 4C)*
- *alveolar cleft (Fig. 5 and 6).*



Cleft lip



Unilateral labio-alveolar cleft

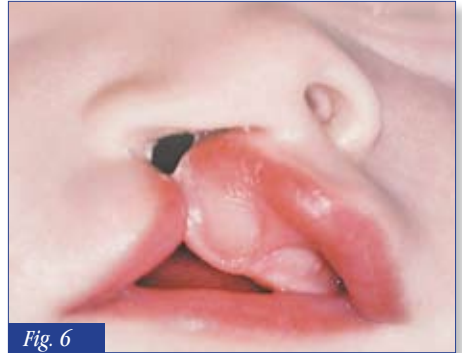Secondary palate

This is the true palate, formed of an anterior bony part (*hard palate*) and a posterior part (*soft palate*). The secondary palate forms between the seventh and eleventh weeks.

Many varieties of clefts can occur, depending on the region involved by the malformation. We may have a complete bilateral cleft of the structures of both primary and secondary palates or, on the contrary, a partial cleft only involving part of the lip on one side or only part of the soft palate. Figures 4 to 9 show the commonest clefts, all of which can be unilateral or bilateral. In ascending order of seriousness we might mention:

Clefts of the secondary palate

- ***bifid uvula*** is a “minor” form involving only the **uvula** (the “grape-like” appendage at the rear of the soft palate). Another minimal form is the *submucous palatal cleft*, which is not easily detectable as it only involves the deep layers of the secondary palate and not its surface. Both forms are rare.
- ***cleft of the soft palate***, partial or complete.
- ***cleft palate*** (hard and soft palate) (illustrations Fig. 7 and 8).
- ***Pierre Robin Sequence*** (Fig. 3, page 12) is a particular anomaly associating ***micrognathia*** (small lower jaw) and ***glossoptosis*** (the tongue is set too far back and high, in a more or less extensive cleft palate). Neonates with this anomaly may suffer breathing and feeding difficulties in their first weeks of life.



Right complete labio-alveolar cleft

Clefts of primary and secondary palate

- ***unilateral or bilateral cleft lip and palate (CLP)*** (Fig. 9). Around the seventh week of gestation the embryo’s developing face consists of various processes (Fig. 10). At this time one might say that there is a natural total bilateral cleft lip and palate (CLP), for the nasal, labial and maxillary processes are still to come into

Feeding the baby

Chapter 2

The first preoccupations and worries faced by parents, especially the mother, of a baby with a congenital facial cleft relate to feeding. The problems incite fear, and are amplified and exaggerated before a satisfactory and reassuring solution can be found. The mother can recover her serenity only when she realises that feeding her baby is indeed possible, admittedly with certain adaptations depending on the type and severity of the cleft.

All mothers are apprehensive when faced with real or imagined difficulties that her child might encounter. She fears that he will suffer, and not gain weight quickly enough, that she will not

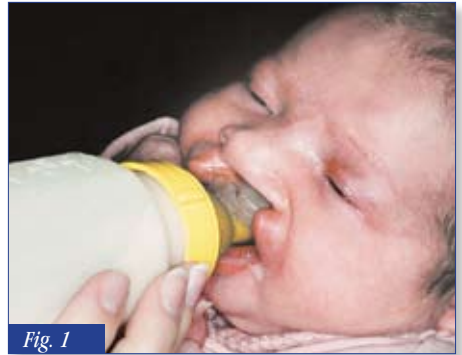

Fig. 1

After fitting a feeding plate the baby can easily be fed by bottle

be able to cope, or adapt to her child and meet all his needs. These fears create and maintain a state of stress which is not propitious to establishing the immediate, comfortable relationship which is necessary for the baby's prime need: to feed. In spite of a sometimes difficult beginning, experience shows that the situation can very quickly improve, especially after the fitting of a feeding plate.

The baby's feeding difficulties depend on the type and severity of the malformation. They also depend on the baby's own capability and what we refer to as the "tonus" of his neuromuscular system. Breast feeding, universally highly recom-

Dental sequelae Orthodontics

CHAPTER 3

CLP can affect the teeth in various ways. Both deciduous (milk) teeth and permanent teeth can be affected in terms of shape, size, number and position. It is mostly the incisors, the teeth in the direct neighbourhood of the cleft, which are involved. A cleft of the alveolar process is generally at the site of the future canine and lateral incisor.

The dental sequelae of CLP are cosmetic, but also affect the masticatory (*chewing*) function of the patient. So their treatment is an absolute priority for the patient, to which the team's orthodontist and maxillofacial surgeon contribute actively.

The efficiency of their treatment depends on perfect coordination and planning, paying attention to the wishes expressed by the patient, but equally to factors related to growth and craniofacial development. In other words, any intervention must depend on its usefulness and the long-term benefits it can achieve for the patient.

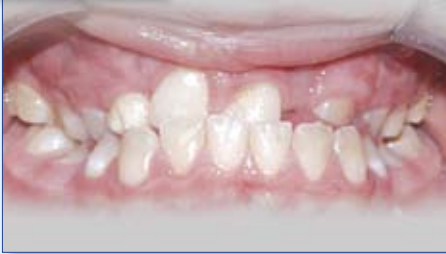Orthodontic treatment may be long, but must not be started too early in order to avoid tiring the patient, whose cooperation is indispensable during the later stages of the treatment, toward the end of his growth period.

Teeth near the cleft may present a malformation of their crown with for example anomalies of mineralization or calcification of the enamel (*the superficial layer of the tooth*), giving an irregular appearance to its surface or visible as brownish patches. We call this **enamel hypoplasia** (*arrows in Fig. 1*).

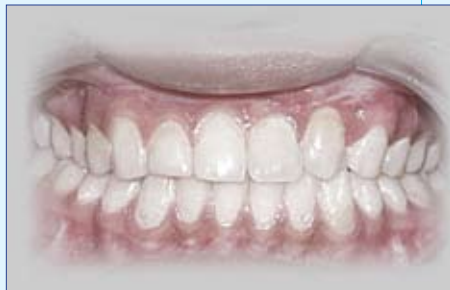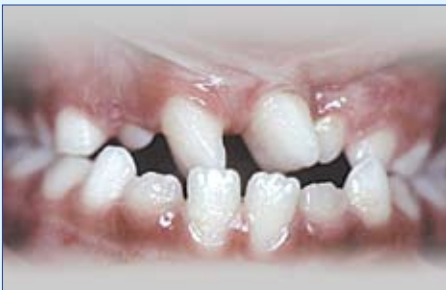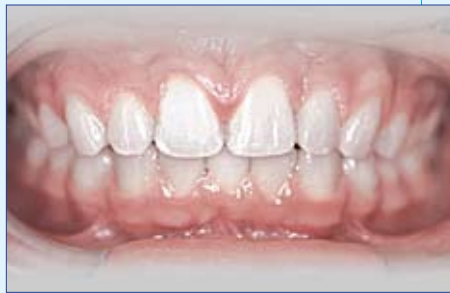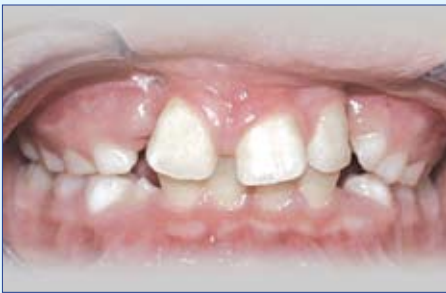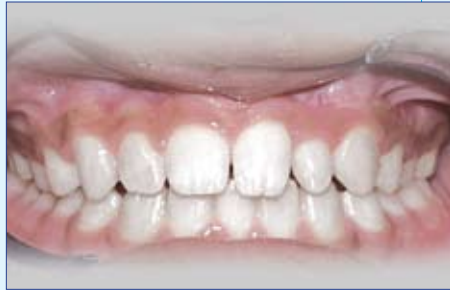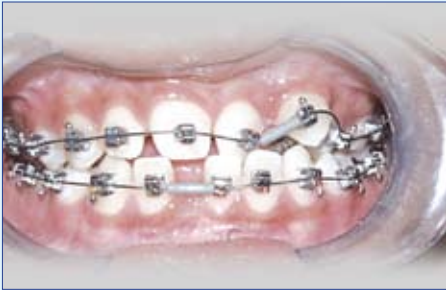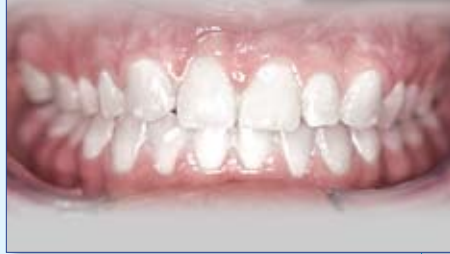The front teeth (*incisors and canines, Fig. 1 to 3*) often erupt in an abnormal position and may present various degrees of **rotation**, abnormal **inclination**, or **crossbite** (*x*) with their antagonists in the lower jaw. The lateral incisor may be absent (*agenesis*). A recent study (*Cassolato et al., 2009¹²*) reported that 76% of individuals with a complete cleft of the lip and palate had a missing lateral incisor on the side of the cleft. When present, the lateral incisor was abnormal in shape and/or size in 96.4% of the cases. On the contrary

Some examples of the outcome of orthodontic treatment

Before treatment



After treatment



The alveolar cleft

Alveolar bone graft

*A*mong the sequelae of CLP, those concerning the alveolar region specifically affect the teeth, from their formation to their eruption, and also the development and quality of their supporting tissues. In the region of the incisors and the canines the absence of bone has a negative effect on the dentition and its periodontal support. It is extremely important to correct this by well-timed intervention to minimise these sequelae and enable the harmonious development of the teeth. Beyond the alveolar region itself, which is related to the cleft, there can be negative effects on the development and stability of the upper jaw due to the absence of continuity between the segments separated by the cleft. An alveolar bone graft represents a decisive and indispensable stage in the dental rehabilitation of young patients with this type of malformation.

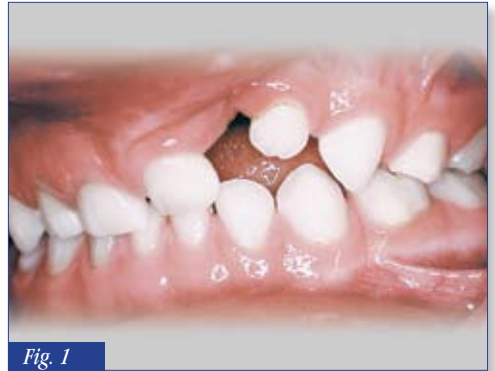

Fig. 1

Deciduous dentition with a complete unilateral left CLP

Orthodontic treatment

Deciduous dentition

(up to about 7 years old)

During this period one never attempts orthodontic treatment. Various forms of malposition of the deciduous teeth, even if quite serious, are usually not treated because of the transitory nature of this stage of dentition (Fig. 1). One wishes to avoid seeking the cooperation of the young child too soon by imposing appliances which, most often, are not indispensable. Intervention is restricted to monitoring progress by examinations every 18 months or so. Parents are advised to pay attention to necessary oral and dental hygiene from the youngest age.

Mixed dentition (7 to 12 years old)

In children with sequelae of uni- or bilateral CLP, the priority during the period of mixed dentition is to permit the natural harmonious development of the teeth and gums as far as possible without major dental appliances.

Basically, the main dental and orthodontic concerns are related to the planning and preparation for an alveolar bone graft, the priority in these young patients.

Permanent dentition

Orthodontic treatment for permanent teeth was the topic of the previous chapter. Each case presents its own difficulties, necessitating individual treatment, sometimes long and difficult. Treatment will always be easier and give better results when an alveolar bone graft is performed at the right time by a specialised maxillofacial surgeon.

Unfortunately one still encounters patients who have not benefited from such a graft, either from a lack of coordination or of competence. Figure 2 illustrates a difficult situation when the absence of a bone graft is felt acutely. It is not possible to close up the teeth adjacent to the cleft, and reconstruction using an implant is not possible

due to the absence of bone and the persistence of a wide alveolar cleft. The patient is “condemned” to wear a removable prosthesis, for even a prosthetic bridge cannot be fitted in such conditions!

Alveolar bone graft

When and why should an alveolar bone graft be planned?

To determine the ideal age for this operation, an X-ray examination at the age of eight or nine

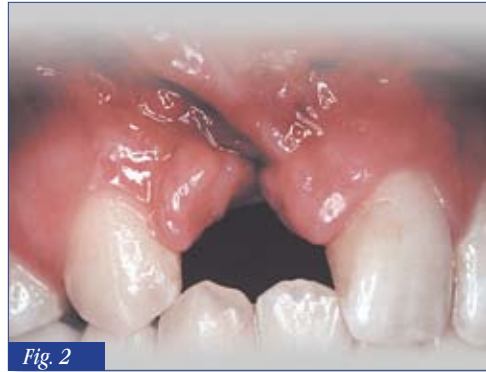

Fig. 2

Residual alveolar cleft in the absence of a bone graft

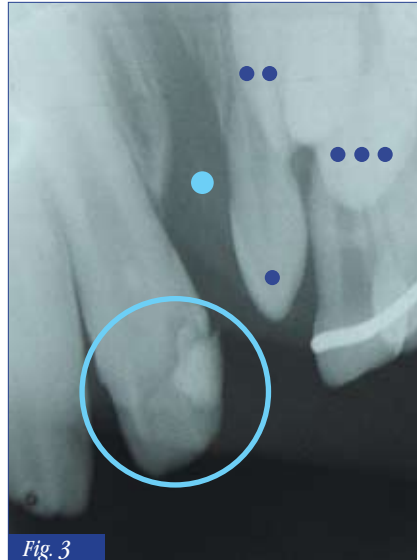

Fig. 3

The lateral incisor • is peg-shaped. Canine •• and premolar ••• are still above the deciduous teeth.

Speech

with the contribution of
Chantal Zbinden-Trichet

*Speech pathologist with the
Cleft Palate Teams of Paris
(Hôpitaux Trousseau et Robert Debré)
and Lausanne (CHUV)*

The phonemes, the sounds we emit, are produced by the flow of air from the lungs via the bronchi first, then the trachea, the larynx, the pharynx and finally the buccal cavity or mouth. The vocal cords are in the larynx. To speak we vibrate these cords while bringing them close together. These vibrations produce the sound.

We can modulate the sounds, and control their intensity and tone, by changing the pressure of the air from the lungs and by changing the length and position of the vocal cords. Children with a cleft palate have normal lungs, trachea, vocal cords and larynx. However they often have specific difficulties related to their congenital malformation and its multiple anatomical and functional consequences.

The main speech problem that they may present relates to one of the functions of the soft palate which consists of orientating and regulating the expired airflow to the mouth or nose. If this does not happen, **velopharyngeal incompetence**, it may result in an audible and annoying **nasal emission** during speaking.

Production of phonemes

Vowels

Vowels are mainly distinguished by their quality and basic pitch. Try saying “ah” then “ee”, and you will feel the change in position of your tongue. Vowels are produced by a series of “sound boxes”, anatomical cavities which modify the nature of a sound. There are the buccal cavity (*mouth*), the throat and the nasal cavities. We can produce different vowels by changing the shape and size of the cavities. The volume of the buccal cavity can be changed mainly by the action of the tongue and lips.

The nasal cavities play an equally important role in the production of vowels. They communicate with the buccal cavity when we breathe and are not speaking. When we speak the soft palate plays the role of a valve and rises to prevent ex-

Primary surgery

Chapter 6

Dr Judith Hohlfeld

*Head, dept. of pediatric surgery
CHUV, Lausanne*

All specialists agree that CLP must be operated on relatively early, but controversy persists concerning the technique to use and the timing. Ideally one would prefer to close these clefts as early as possible, even before birth. Intra-uterine surgery for clefts has been tried on laboratory animals, but it still involves far too many risks and unknowns to be applied to the human foetus.

Operative technique and timing: the controversy

In some centres the cleft lip is operated on in the first few days of life. We consider that the advantages do not justify the risks. The advantages are undeniable, above all for the parents, and especially the mother, who can leave hospital with the baby and show him off with pride, and probably more easily adapt to the malformation and its consequences, at least in the short term. Still, we believe that these advantages do not outweigh the operative risks for the child.

At three months the baby tolerates the operative stress much better thanks to a considerable weight gain and better resistance to infections. Further, his overall growth, especially that of the maxilla, leads to a marked reduction in the width of the cleft. The surgeon can then close the cleft using noticeably less tension. The risk of the sutures bursting and secondary unfavourable effects on later maxillary growth are reduced. The post-operative course is uncomplicated and hospital stay averages 48 hours post-operative.

The technique and timing of the closure of a cleft palate are still the factors which give rise to the greatest controversy among specialists. Many studies have shown that too early closure and a traumatic technique (*closure under too much tension, too extensive undermining of the mucosa, or the production of too much scar tissue in sensitive growth areas*) have very unfavourable consequences on the growth of the maxilla, the later alignment of the teeth and final dental occlusion. On the contrary, too late closure of a

cleft palate (*at age four or five or even later*), which offers advantages in terms of harmonious growth of the maxilla, has serious consequences on the quality of the patient's speech. Errors in articulation and severe hypernasality will be difficult, if not impossible, to correct later. One must find a compromise: operate on the palate early enough to enable the child to develop optimal speech, but not too early, in order not to compromise later maxillary growth. Timing is certainly an important factor but the mastery of technique by the surgeon, acquired by specialised training and maintained by long experience of many cases operated each year, is the most important to guarantee optimal, consistent and reliable results.

“Malek” technique

Our multidisciplinary team has opted for the technique and timing according to Dr René Malek of Paris, which offer an excellent compromise of early repair and relatively atraumatic technique.

The first operation at three months is the **veloplasty**: closure of the soft palate. By closing the cleft in the soft palate, we obtain early recovery of its muscular function, very important for later development of speech. Once the soft palate is closed, we observe a spontaneous, rapid reduction in width of the whole residual cleft, helped by the fitting of a palatal plate during the whole period from birth on and between the first and second operations.

The hard palate and alveolar clefts are narrower at the time of their surgical closure at six months of age. They can be closed more easily, using less undermining of the mucosa and involving much less tension. The later growth of the maxilla will suffer less inhibition.

The indications for and use of the palatal (*feeding*) plate were described in Chapter 2. It helps the child feed and makes the tongue adopt a more normal horizontal position, which it will keep after the surgical closure of the palate. One regularly sees that after surgery children are already comfortable with their new anatomy when

a plate has been used, and feed more easily. Furthermore the plate protects the sutures from rubbing or sucking due to movements of the tongue during the postoperative healing period.

CLP is closed in two stages: at three and six months if unilateral, or three stages (*three, six and eight months*) if bilateral. Isolated cleft palate is closed between three and nine months depending on its size, and the timing is discussed with the surgeon beforehand. Cleft lip, with or without alveolar cleft, but not involving the palate, can be closed at three months.

Veloplasty (*surgical closure of the soft palate*)

Veloplasty is the first operation in the reconstruction of unilateral or bilateral CLP. As the baby's mouth is small at the age of 3 months, a specially designed **mouth-gag** is used to gently open the mouth. Before the start of the operation a solution of adrenaline and local anaesthetic is injected in the palate to minimise blood loss. In this way the child will not need a blood transfusion. The surgeon can operate faster and with more precision.

In Figure 1 we see the limit between the hard and soft palate and the incisions at the edges of the cleft, which enable the muscles of the soft palate to be brought to the midline. Where the muscles are inserted laterally, we identify a small bony projection, the **hamulus of the sphenoid bone**, and gently move it toward the midline to the position it would have if there was no cleft. This movement relaxes the muscles and allows the surgeon to suture the two sides together with very fine sutures in two layers (*Fig. 2*).

There is more tension on the sutures in the anterior part of the palate because the tissues are more difficult to mobilise. So we use a small flap of mucosa taken from the nasal septum and turned backward to cover this zone under tension. At the sides where the muscles have been freed, the small wounds will heal very quickly and will close within a week. The palatal plate is replaced at the end of the operation.

Ear, nose and throat (ENT) problems

Dr Jacques Cherpillod

*ENT FMH, audiophonologist
ENT dept. CHUV, and Hôpital
de l'Enfance, Lausanne*

As we might imagine, the various malformations and deformations of the anatomy of the nose, mouth and pharynx associated with facial clefts can precipitate local problems.

ENT problems frequently encountered in children with cleft palate:

- *repeated acute otitis media or chronic (long-lasting) secretory otitis media*
- *partial nasal obstruction provoking mouth breathing and “colds”*
- *a too short soft palate with sometimes a small residual fistula in the palate causing hypernasality and sometimes reflux of food in the nose while feeding.*

Acute otitis media and secretory otitis

The ear consists of three parts (*Fig. 1*):

- *the external ear, consisting of the pavilion and the external auditory meatus*
- *the middle ear, from the eardrum externally, containing the ossicles, which act as an amplifier. If they are damaged, one can no longer hear a human voice speaking normally. The middle ear is normally filled with air, regularly topped up through a canal from the back of the nose, the Eustachian tube.*
- *the inner ear, where sound vibrations are transformed to electrical signals and then transmitted to the brain through the auditory nerve. It also contains organs of balance (the vestibular system).*

In order to function properly, the middle ear must regularly receive fresh air from the **Eustachian tube**, which is normally closed to prevent infection from the nose entering the ear. It opens by the contraction of two muscles when we swallow or yawn. We can also open it voluntarily by pinching our nose and blowing. We are familiar with this when we do it as we change altitude. Generally, this opening mechanism does not function fully until the age of 6 to 8, which is why children are more susceptible to ear prob-

Chapter 8

Maxillofacial
surgery

Chapter 8

Prof. Bertrand Jaques

*Head, unit of maxillofacial surgery
dept. ENT, CHUV, Lausanne*

The role of maxillofacial (*jaw*) surgery

The bony structure of the jaws may be affected more or less extensively, depending on the severity of the malformation. This might affect only a minor part of the alveolar process, termed an alveolar notch. On the other hand, it can affect the whole maxilla from the anterior alveolar portion to the rear limit of the hard palate. As we have seen, it can also affect more or less of the soft tissues ahead of the bony palate (lip and gum), or behind it (soft palate). Furthermore it can be uni- or bilateral.

The central problem is that there is a bony defect in a more or less extensive part of the maxilla. The sequence of bony interventions in the treatment of clefts and related malformations can in general be conceived as follows:

- *alveolar bone graft*
- *correction of major bony structures.*

These two stages of treatment take place at very different ages.

Alveolar bone graft

This operation aims to fill the gap in the bone on the front of the maxilla, where the permanent teeth will erupt. The missing bone is replaced by bone taken from another site.

The only way to guarantee that the transplanted bone will take and not be rejected is to use bone from the patient himself, that is to say an autograft. Bone from another human subject (*allograft*) or another animal (*xenograft*) or some sort of synthetic bone does not give satisfactory results and leads to considerable complications and is therefore not recommended in these cases.

Whether uni- or bilateral, an alveolar cleft is usually situated between the canine tooth and the lateral incisor. In terms of timing, it is important to perform an alveolar bone graft before

Rhinoplasty

Chapter 9

Prof. Philippe Pasche

ENT FMH, dept. ENT,
CHUV, Lausanne

In many individuals born with a facial cleft, sequelae in the form of deformations of the lips and/or nose are observed. As far as the nose is concerned, they affect its external anatomy and its symmetry. They result from anomalies of the nasal septum and, more superficially, of the nasal bone, nasal cartilages, neighbouring bony structures, as well as of the soft tissue covering the nose.

The nostrils may appear asymmetric, with the side of the cleft being flattened. The wing of the nose lacks support due to defects of the lateral cartilages and deviation of bony structures such as the anterior nasal spine on the front of the maxilla. The columella (*the external end of the septum*) is short and is deviated to the side opposite the cleft. In the case of bilateral cleft, the columella is less deviated but often much shorter.

Nasal deformation is not always fully obvious in infancy or pre-adolescence. It may worsen during the pubertal growth period. In the least favourable cases, if surgical correction of the jaws (*orthognathic maxillofacial surgery, see Chapter 8*) is indicated at the end of growth, the shape of the nose may be profoundly influenced by the surgery. For this reason one often recommends deferring surgical correction of deformation and asymmetry of the nose (*rhinoplasty*) and planning it as a last resort, after growth is completed and after any maxillofacial surgery. This is **late** rhinoplasty as opposed to **early** or **intermediate**.

Rhinoplasty is the surgical correction of nasal malformations or deformations, common sequelae of cleft lip with or without cleft of the palate. Its aim is not only to correct the shape of the nose but also to improve respiratory function which is often affected on the side of the cleft. Respiratory difficulties stem from a reduced opening of the nostril (*flattening of the nostril on the side of the cleft*) and from deformation and deviation of the nasal septum. It is thus obviously an operation motivated by cosmetic criteria but which is justified just as much by functional necessity and to improve the patient's everyday comfort.

Anatomy

The nose is built around a framework of bone and cartilage. The bridge of the nose consists, in its upper part, of the nasal bones and inferiorly by the **septal** and **lateral** cartilages. The tip of the nose contains two curved **alar cartilages** (Fig. 1).

With a unilateral cleft, the malformation concerns essentially the nasal septum and the alar cartilage, which is flattened and lowered. This results in asymmetry of the tip of the nose with one enlarged nostril (Fig. 2). In bilateral cleft both cartilages are low with the nostrils almost horizontal. In consequence, the tip of the nose is often flattened.

Rhinoplasty

It can be undertaken at different ages and combined with other operations (Fig. 3):

1. **early rhinoplasty:** performed before the end of the first year of life by some surgeons, at the same time as primary labioplasty. It involves too many difficulties and risks, notably in terms of its negative influence on later growth of the nose in the baby and young child. We do not recommend it for these reasons.
2. **intermediate rhinoplasty:** done between 5 and 10 years of age, in so far as the child's collaboration permits. It is reserved for cases of particularly severe deformation, or when the child suffers psychologically and socially, or is the object of bullying. Both objective and subjective indications are taken into account. The operation consists of repositioning the alar cartilage through an incision inside the nostril. It can be done as an outpatient. A **thermoformable** splint is left in place for 10 days. A dilator or **stent** is fitted in the nostril and must be worn day and night for two to three

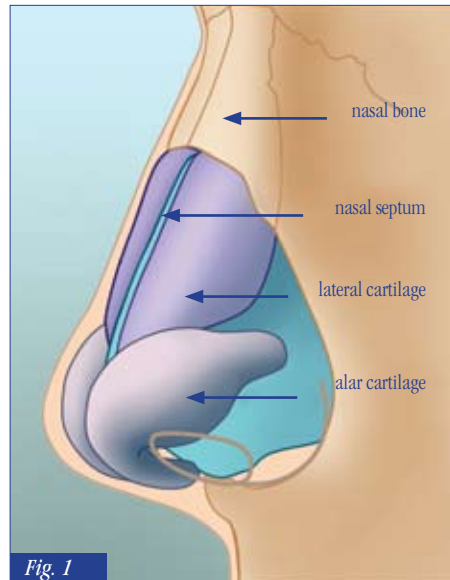


Fig. 1

Normal anatomical structures of the nose

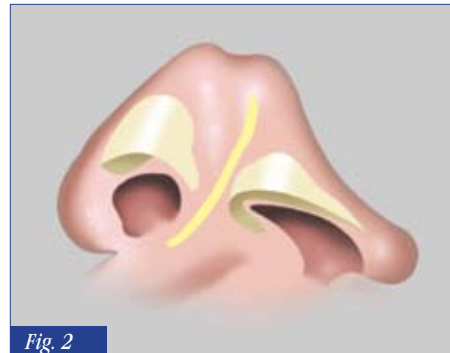


Fig. 2

Deformation of the alar cartilage in the presence of a unilateral cleft of the lip and palate

months (Fig. 4 and 5). The absolute necessity to wear this stent demands active cooperation by the young patient. This obligation must be fully understood by the patient and his parents in order to ensure the best possible healing conditions and to achieve an optimal result. In the case of a bilateral cleft, the operation consists of lengthening the tip of the nose, which is often too short.

No more a child, soon an adult: this is for you

Since you were born your parents have taken all the decisions about your well-being and the treatment you needed. They had to take on the responsibility, sometimes alone, sometimes with the help of a multidisciplinary care team, and the worries associated with the consequences and treatment of the cleft you were born with. Now you are old enough to share these decisions, and even take them for yourself, it is important that you get all useful information to understand the sometimes complex problems about your malformation and its consequences.

This information can be given to you first and foremost by your parents, so you must be able to have a frank and constant dialogue with them. From the very beginning, they received a lot of information, which they really needed. So your parents are well placed to inform you of numerous details about yourself. There are also the doctors and other team members whom you know and whom you can always ask for help on all the subjects and problems that worry you. Sometimes it is useful to be able to read, in a book like this one, in a specialised pamphlet, or on the Internet, about things which concern you directly and intimately. This chapter is dedicated to helping you in this search. That is why we are writing to you directly.

To begin with, we shall deal with the difficult subject of the mechanism and cause of facial clefts. After your birth you underwent one or several operations to close your cleft. Your parents lived through these operations with great anxiety because for them it was extremely hard and painful to take their baby to hospital to have surgery. But at the same time they maintained the great hope of seeing you regain your physical ability to feed and develop completely normally.

Support groups and help from the web

When a baby with a congenital malformation is born, parents may have been at least partially prepared if there was an antenatal diagnosis by ultrasound. On the other hand, very often the malformation is not at all expected and the terrified and anxious parents discover it brutally. At first a multitude of questions baunt their minds without finding ready answers. They are overwhelmed by uncertainty and worried by the vastness of the problems awaiting them.

Many people, other parents, sometimes just around the corner quite close to them, have also known such turmoil in their lives. Others before them have wept and felt powerless, angry, sickened, or resigned. Many are living with them today. Countless others will know them tomorrow, throughout the world. Some of these people have been able to express their feelings and describe their experiences in simple but emotionally charged words, as in the following open letter.

The author of this letter is the wife of a former professor of orthodontics at the University of Rochester, New York, and mother of Greg, born in the 1950s with a CLP. She became a well-known speech and language expert, specialising in problems related to facial clefts. Her son is a dentist today, who has been in private practice for many years.

Her message is clear: parents often feel helpless and overwhelmed, and live the first months after the birth of a baby with a facial cleft as a series of difficulties in adapting. They desperately need help. This help exists and they must not hesitate to seek it.

Psychological impact of antenatal diagnosis on the future parents

Josée Despars,
Psychologist ESP, Ph.D.

*Division of Psychiatry
of the Child and Adolescent, SUPEA,
PELL, CHUV, Lausanne*

Significant technological progress has been achieved in the field of diagnosis by ultrasound which allows us in some cases to detect a facial cleft before birth. Antenatal diagnosis mainly concerns cleft of the lip and alveolus, either uni- or bilateral. Isolated cleft palate can only be seen rarely in this way. The reliability of this diagnosis is limited by factors such as the position of the foetus and an insufficient volume of amniotic fluid. The best time to perform this diagnostic examination is in the middle of the second trimester.

From the moment that the antenatal diagnosis of a facial malformation has been made, numerous questions torment the parents (*see also Chapter 13*). What is it? Is it an isolated cleft? Are there malformations elsewhere? This diagnosis leaves the parents in a daze. Time passes differently. The present suddenly becomes indescribable and uncertain. It is either impossible to imagine the child, or on the contrary a flood of images invades the parents' minds. Confronted by thoughts of loss and deficiency, the parents must go beyond the diagnosis in order to accept the child. The story of the birth of a child with a cleft is one of an unexpected and strange encounter. It presents the parents with questions of where and why and how. It challenges the development of the parent-child relationship and the child's future.

Progress in surgery today allow for high aesthetic and functional results. In spite of professional competence and the information that the parents will gather, preoccupations often remain. They concern the aesthetic quality of the expected results, fears about feeding and language development, or aspects of the different operations to be undergone, such as pain and subjective experience. Faced with such complexity, normal landmarks may be temporarily lost. Individual resources and specificities play an important role and it is impossible to predict the future of the child and his relationship to his parents. A few points of reference may be able to assist parents face their difficulties and seek help when needed.

So many questions...

Chapter 13

Certain anxieties and numerous uncertainties assail the new parents confronted with what for them, in most cases, is a future of largely unknown difficulties for them and their child.

Thousands of questions invade their minds sometimes leading to discouragement and even despair when facing the problems they have to resolve. This, more than their absence of previous personal experience, makes it difficult for them to judge the complexity or the evolution of these problems. Here we suggest replies to some of the burning questions. Others will occur to parents at some time or other during the growth and development of their child. Those questions which cannot be answered here must not remain unanswered but must be brought up with the specialists of the team, always ready and willing to try to offer the required information as far as they can and as far as present knowledge in the field allows.

What is the cause of facial cleft?

There is no single cause. Genetic factors probably play a major role. Some clefts are associated with other malformations (*syndromes*) and have a genetic origin. There are families in which one or more cases have occurred in the past. This recurrence can be partly explained by the existence of a predisposition, probably genetic, in the family members. In many cases environmental factors are also involved, such as medication, drugs, smoke or vitamin deficiency, but their exact influence is not known. In most cases, genes and environment are combined.

What is certain is that parents are not responsible and should therefore not harbour a feeling of guilt. In short, we must admit that in most cases the cause of a cleft is not known with certainty.