

# Neurosciences Update

Neurosciences News From Mayo Clinic Vol. 18, No. 4, 2021

SEPTEMBER 2021

## In this issue

- 3 Burr Hole Approach Offers Minimally Invasive Option for Resecting Brain Lesions
- 4 NF2 Clinic: Proactive, Coordinated, Multidisciplinary Care
- 6 Robot-Assisted Spinal Surgery Shows Promising Initial Results

## Novel Endovascular Therapy for CSF-Venous Fistulas

Mayo Clinic has reported the first case series of transvenous embolization of paraspinal veins to treat cerebral spinal fluid (CSF)-venous fistulas. The innovative therapy resulted in clinical and radiographic improvement and no permanent complications in all participants in the small case series.

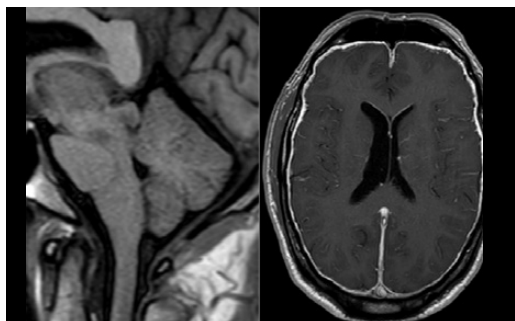
“It’s a significant advance in the treatment of CSF-venous fistulas,” says Waleed Brinjikji, M.D., a neurointerventionalist at Mayo Clinic in Rochester, Minnesota. “We are able to fix these fistulas and send patients home the same day, without worrying about the complications that can occur with spinal surgery.”

CSF-venous fistulas, first described in 2014, are increasingly recognized as a cause of spontaneous intracranial hypotension. “We are finding that, in at least

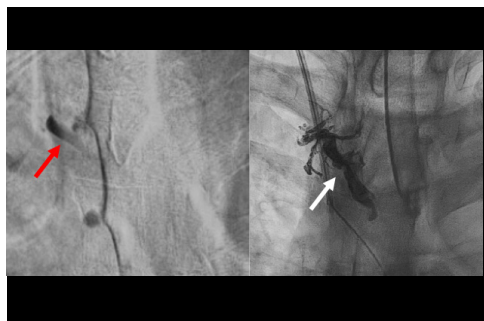a quarter of people with a CSF leak, it’s due to a fistula. That is a major subgroup, and we expect it to grow as our diagnostic techniques advance,” says Jeremy K. Cutsforth-Gregory, M.D., a neurologist who leads the CSF dynamics clinic at Mayo Clinic’s campus in Rochester.

The most effective treatment for a CSF-venous fistula has been surgical intervention that includes laminectomy, facetectomy and ligation of the nerve root and associated veins. Although the procedure can ease the severe headaches associated with intracranial hypotension, it requires a hospital stay and lengthy recovery.

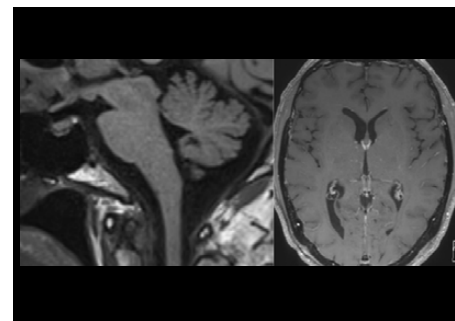
“Spinal surgery is significantly more invasive than the endovascular intervention that we developed,” says Luis E. Savastano, M.D., Ph.D., a cerebrovascular



**Figure 1.** Preoperative MRI of a participant in Mayo Clinic’s case series shows signs of brain sag with flattening of the pons, reduced mammillopontine distance and effacement of the suprasellar cistern, as well as thick pachymeningeal enhancement.



**Figure 2.** On the left, digital subtraction myelogram shows a large CSF-venous fistula at right T4 with filling of the right T4 paraspinal vein (red arrow). On the right, the patient underwent successful embolization of the vein (white arrow).



**Figure 3.** Postoperative MRI shows resolution of the brain sag and meningeal enhancement.



Waleed Brinjikji, M.D.

neurosurgeon at Mayo Clinic’s campus in Rochester. “In addition to long recovery times, many patients also experience new numbness and pain at the surgical site that lingers for months.”

Existing minimally invasive treatment options, such as epidural blood patch and fibrin glue injection, have been effective in only a tiny minority of patients with fistulas. “Embolization seemed like a feasible alternative, as long as we could navigate through the paraspinal venous system and get our catheter to the exact right point,” Dr. Brinjikji says.

Dr. Brinjikji had acquired a medical textbook from the 1970s on spinal phlebography, a common diagnostic tool before MRI. “We realized that if physicians could get into the paraspinal veins back then, we — with all the advances in catheterization — should be able to get into them and block them off using our newer and safer embolic agents,” he says.

#### DSM TO LOCALIZE FISTULAS

As described in the May 2021 issue of *American Journal of Neuroradiology*, the Mayo Clinic case series included five patients with CSF hypotension secondary to CSF-venous fistulas. The patients’ fistulas were localized using lateral decubitus digital subtraction myelography (DSM). On MRI, all patients had evidence of CSF hypovolemia, including brain sag and pachymeningeal enhancement (Figure 1, see page 1) with no extradural fluid collection on total spine MRI.

The endovascular procedures — performed in August 2020 — involved catheterization of the azygous vein, followed by selective catheterization and embolization of the paraspinal vein (Figure 2, see page 1).

All patients had improved clinical and radiologic findings (Figure 3, see page 1) after the procedure. Four patients had complete resolution of headaches, and one had a 50% reduction in headache symptoms. Brain sag resolved in four patients and improved but did not resolve in one patient. Similarly, pachymeningeal enhancement resolved

in four patients and improved but did not resolve in one patient.

“Patient satisfaction has been very high, and we are very rigorous in obtaining complete clinical and imaging follow-up on all patients,” Dr. Brinjikji says.

Pain localized to the site of the embolization was a common minor complication, but no patient required narcotics. And the pain subsided in a matter of weeks for all patients. No patient experienced permanent neurological complications. The researchers note that further studies are needed to confirm the technique and to validate the treatment’s durability.

An essential component of this procedure is state-of-the-art imaging for the diagnosis of CSF-venous fistulas.

“Identifying the fistula is a major challenge,” Dr. Cutsforth-Gregory says. “DSM allows us to locate fistulas that might otherwise be overlooked. It’s practice changing.” Currently, eight DSMs a week are routinely performed at the Rochester campus of Mayo Clinic, making it one of the highest-volume CSF-leak practices in the world.

The development of innovative treatments is facilitated by Mayo Clinic’s multidisciplinary approach. “This new endovascular treatment modality is the result of teamwork by highly skilled headache neurologists, interventional neuroradiologists and endovascular neurosurgeons, as well as a radiology team at the forefront of medical imaging,” Dr. Savastano says.

“Historically, endovascular approaches have been used to fix only vascular problems,” he adds. “This treatment represents a paradigm shift. We are now using endovascular procedures to fix problems outside the vessels themselves.”

#### FOR MORE INFORMATION

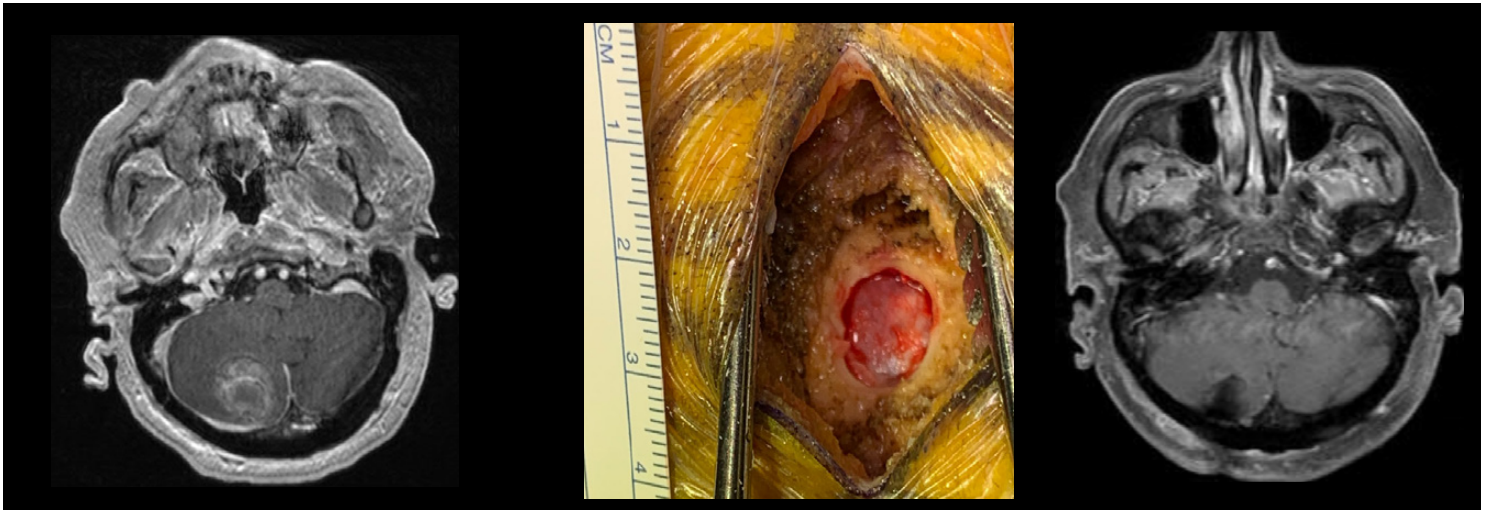Brinjikji W, et al. A novel endovascular therapy for CSF hypotension secondary to CSF-venous fistulas. *American Journal of Neuroradiology*. 2021;42:882.



Jeremy K. Cutsforth-Gregory, M.D.



Luis E. Savastano, M.D., Ph.D.



**Figure.** On the left, preoperative MRI shows a large cerebellar metastatic tumor. The center photograph shows the burr hole, measuring less than 14 millimeters, through which the large cerebellar tumor was resected. On the right, postoperative MRI shows complete resection of the large tumor. The patient went home on the day following the procedure.

## Burr Hole Approach Offers Minimally Invasive Option for Resecting Brain Lesions

Mayo Clinic has successfully performed a series of intra-axial tumor resections using a burr hole approach with exoscopic visualization. The procedures, described in a study published in the March 2021 issue of *Journal of Neurological Surgery*, provide proof of concept for this minimally invasive approach (Figure).

“This approach represents the extreme boundary of keyhole surgery. We have been able to resect select tumors through a 14-millimeter burr hole, similar to what is used for a needle biopsy,” says Kaisorn L. Chaichana, M.D., a neurosurgeon at Mayo Clinic in Jacksonville, Florida. “Patients generally go home the following day and recover much faster.”

Fourteen (93%) of the 15 patients in the Mayo Clinic study had gross total resection. The tumor remaining in one patient was minimal and subsequently resected. None of the 15 patients experienced complications after the burr hole procedure, and a majority went home the next day.

“The incision is very small — about three-fourths of an inch — and blood loss is much lower than with conventional surgery,” Dr. Chaichana says.

Exoscopic visualization is the key to this approach. Compared with the endoscope, the exoscope provides a wider focus of view,

greater magnification and oblique visualization angles.

“Our goal in this surgical series, as with all our patients, was to achieve maximal, safe resection,” Dr. Chaichana says. “The exoscope, as opposed to the endoscope, hovers over the surgical field, not within the cavity. It provides a wider focus of view, greater magnification and oblique visualization angles that would be nonergonomic compared with the surgical microscope.”

The burr hole approach is suitable for resecting superficial lesions. All tumors in the patients treated in the Mayo Clinic series were in close proximity to the cortical surface, with the most superficial part of the lesions located above the sulcal boundary in the coronal plane.

Patients with lesions presumed to be close to eloquent areas had functional MRI and diffusion tensor imaging before surgery. If access to the lesion required cortical or subcortical violation of eloquent areas, the burr hole approach wasn’t used.

Among the patients studied, eight had metastatic brain tumors, four had low-grade glioma and three had high-grade glioma. Lesion diameter was typically limited to 4 centimeters. Dr. Chaichana notes that the burr hole procedure is also suitable for evacuating hematomas.



Kaisorn L. Chaichana, M.D.

“A minimally invasive approach means patients heal faster, so they can start radiation and chemotherapy sooner, if needed,” Dr. Chaichana says. “We believe the burr hole approach can be used for selective lesions without compromising the extent of resection or neurological outcomes.”

#### FOR MORE INFORMATION

Marenco-Hillebrand L, et al. Burr hole-based resections of intrinsic brain tumors with exoscopic visualization. *Journal of Neurological Surgery. Part A, Central European Neurosurgery*. 2021;82:105.

## NF2 Clinic: Proactive, Coordinated, Multidisciplinary Care



Matthew L. Carlson, M.D.

Mayo Clinic has launched the multidisciplinary Neurofibromatosis Type 2 Clinic to provide comprehensive management of this uncommon genetic condition. The initiative brings together providers in 12 specialties for the diagnosis and treatment of teenagers and adults with neurofibromatosis 2 (NF2).

“Our mission is to offer highly coordinated care that addresses the multifaceted aspects of the disease,” says Matthew L. Carlson, M.D., an otolaryngologist at Mayo Clinic in Rochester, Minnesota, and director of the NF2 Clinic. “We are committed to being not just reactive but proactive, to anticipate the future needs of patients and their families.”



Dusica Babovic-Vuksanovic, M.D.

Patients referred to the NF2 Clinic typically complete imaging tests and multispecialty examinations and start treatment within a few days. Genetic testing is included.

“We use many new methods of genetic testing on blood samples — and also often on available tumor tissue — to establish genetic variation,” says Dusica Babovic-Vuksanovic, M.D., a medical geneticist at the Rochester campus of Mayo Clinic.

As a major tertiary center, Mayo Clinic uses cutting-edge imaging to monitor tumors associated with NF2. A range of systemic and targeted treatment options are available. Select patients might also be eligible for clinical trials. “Our goal is to be a comprehensive clinic that provides efficient, streamlined care,” Dr. Carlson says.



John (Jack) I. Lane, M.D.

The Neurofibromatosis Clinic at Mayo Clinic in Phoenix, Arizona, provides multidisciplinary care for children and adults with neurofibromatosis type 1 and NF2.

#### MANAGING VARIABLE AND COMPLEX PHENOTYPES

NF2 is characterized by the development

of multiple tumors. Although nearly all patients have bilateral vestibular schwannomas, the number and type of additional tumors differ.

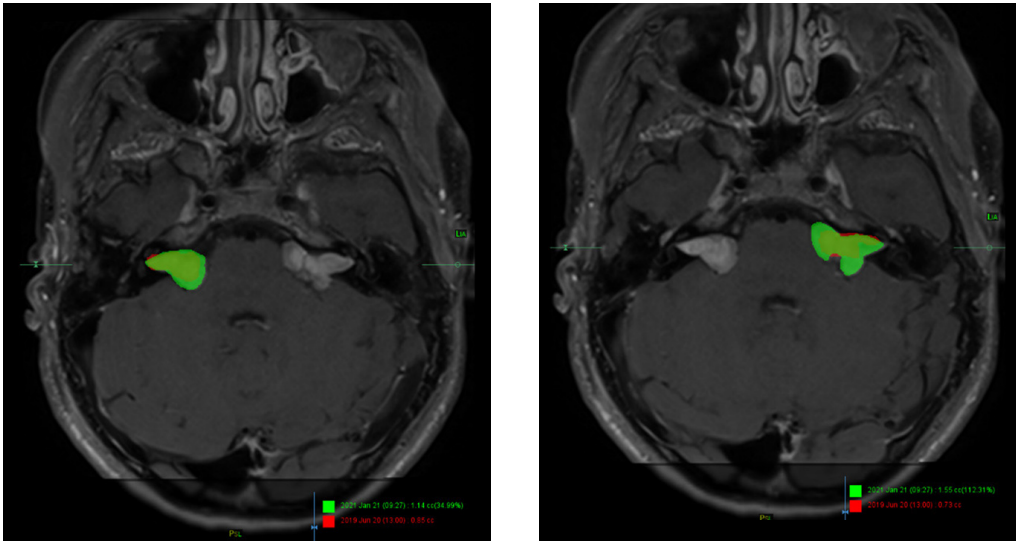
“The phenotype is extremely variable,” Dr. Carlson says. “A patient might be 70 years old and have no features of the disease except two small vestibular schwannomas. But some people have a diagnosis in their teenage years or even earlier and experience very severe disease. An individual may have more than 50 tumors spread throughout the brain, skull base, spine and peripheral nerves.”

Besides affecting the vestibulocochlear nerves, schwannomas can develop in other cranial nerves as well as in the spine and peripheral nerves. Cranial and spinal meningiomas are common; spinal ependymomas also can develop. The tumors can lead to debilitating symptoms including hearing loss, imbalance, facial nerve paralysis, swallowing and speech difficulty, limb weakness, and ocular problems.

“NF2 affects people in many different ways, depending on where the tumors grow,” Dr. Carlson says. “Many patients develop hearing loss to the point of being completely deaf, vision loss to the point of blindness and motor difficulties to the point of losing the ability to walk.”

To address these needs, the NF2 Clinic brings together specialists in:

- Neurology
- Neurosurgery
- Neuroradiology
- Neurotology
- Audiology
- Radiation oncology
- Medical oncology
- Pediatrics
- Ophthalmology, including neuro-ophthalmology and oculoplastic surgery
- Medical genetics



**Figure.** Overlays of MRI demonstrate the growth of bilateral vestibular schwannomas over an 18-month period in a patient with neurofibromatosis type 2. The current tumor volume is shown in green, and the earlier tumor volume in red.

- Physical medicine and rehabilitation, including physical therapy and occupational therapy
- Psychiatry

Specialists in peripheral nerve disorders, speech pathology, and plastic and reconstructive surgery also are part of the treatment team as needed.

### COORDINATED APPOINTMENTS

Before arriving at Mayo’s NF2 Clinic, patients complete an online survey about their symptoms — both physical and emotional — and their quality of life. Clinic visits typically start on a Monday morning, with comprehensive imaging of the cranial nerves and intracranial space, skull base, spine, and other parts of the body as needed.

Later Monday or on Tuesday, patients have comprehensive neurological and audiological evaluations. “The audiology visit might involve just a hearing test, or evaluation or programming for a cochlear implant or an auditory brainstem implant,” Dr. Carlson says.

Patients might also see a medical geneticist. About half of people with NF2 have a family history of the disease, and half present with a new mutation. As an autosomal dominant genetic disorder, NF2 has about a 50% chance of being passed on to children.

“Our genetic counseling can also include referral to Obstetrics and Gynecology for specialized in vitro fertilization,” Dr. Babovic-Vuksanovic says. “If a patient already has a child at risk of NF2, we provide screening and surveillance starting at age 12 because tumors associated with NF2 can occur at an early age.”

On Wednesday morning, the specialists gather to discuss patients’ care. “There are two or three providers for each of the 12 stakeholder specialties — so about 25 to 30 providers during every conference,” Dr. Carlson says. “We start by describing a patient’s overall picture. Then we talk very specifically about the patient’s tumor types and growth.”

Volumetric measurements of tumors — obtained by segmenting and analyzing patients’ MRIs in a 3D laboratory — are assessed. “What might not be readily evident by visual examination of the MRI can be detected with volumetric analysis,” says John (Jack) I. Lane, M.D., a neuroradiologist at the Rochester campus of Mayo Clinic.

Unlike most tumors, which are generally spherical or elliptical, NF2 tumors have highly irregular shapes. “As a result, a 2- or 3-millimeter change on a linear scan can result in a 50% to 80% change in total tumor size, which would be an indication that treatment is needed,” says Michael J. Link, M.D., a neurosurgeon at Mayo Clinic’s campus in Rochester, Minnesota.

The specialists also evaluate overlays of a patient’s current scans and scans taken two years earlier (Figure). “We can drop the previous image right on top of the current image, and then use a slide bar to pan between them,” Dr. Lane says. “Often that analysis can be even more sensitive than volumetric changes in assessing tumor growth.”

Based on these detailed evaluations, the group agrees on treatment recommendations. Patients whose tumors aren’t causing



Michael J. Link, M.D.

problems might have no active treatment. If only one tumor is growing, patients might have localized surgical or radiosurgery treatment. Individuals with multiple, progressing tumors typically have chemotherapy, guided by a neuro-oncologist, medical oncologist or pediatric oncologist.

“Sometimes, treatments are done concurrently,” Dr. Carlson says. “Patients who have multiple tumors, including a large and active tumor, might need surgery or radiation therapy on top of systemic therapy.”

If surgery is recommended, Mayo Clinic neurosurgeons and neurotologists have experience with minimally invasive techniques. The options for radiation therapy include stereotactic radiosurgery — Mayo Clinic has performed Gamma Knife radiosurgery for 30 years — as well as intensity-modulated therapy and proton therapy.

“The multidisciplinary approach is key because the best next steps for patients can vary so much. Everyone on our team has a particular area of expertise,” Dr. Link says. Reconstructive surgery also might be needed to restore facial nerve function and eye closure.

Treatment can start as early as the following day, even if that need wasn’t anticipated before the patient’s arrival. “Certain NF2 care providers have appointment slots set aside. Patients who need radiosurgery, for example, can have it the next day in many cases,” Dr. Carlson says.

Patients seen at the NF2 Clinic might qualify for clinical trials. Mayo Clinic

participates with centers across the United States and around the world in clinical trials of NF2 medications.

“We are looking for ways to apply systemic therapy to prevent the development of tumors,” Dr. Babovic-Vuksanovic says. “It is very important to find alternatives to surgical therapy after tumors develop.”

The emotional health of patients and their families is addressed throughout the process of care. “The secondary sequelae of NF2 are often overlooked,” Dr. Carlson says. “Depression and anxiety are common.”

We think it’s important to approach the patient holistically and to support the family by bringing in a social worker or suggesting family counseling when needed.”

Follow-up visits to the NF2 Clinic are scheduled annually or more frequently as needed. Mayo Clinic is committed to providing lifelong care.

“The magnified care needed by people with NF2 requires the involvement of multiple stakeholders,” Dr. Carlson says. “The cross-talk between specialties is seamless. In our model of care, every provider from each contributing specialty shares a singular goal of achieving the best outcome for each patient.”

#### FOR MORE INFORMATION

Neurofibromatosis Type 2 Clinic. Mayo Clinic. <https://www.mayoclinic.org/departments-centers/neurofibromatosis-type-2-clinic/overview/ovc-20481871>.

## Robot-Assisted Spinal Surgery Shows Promising Initial Results



Mohamad Bydon, M.D.

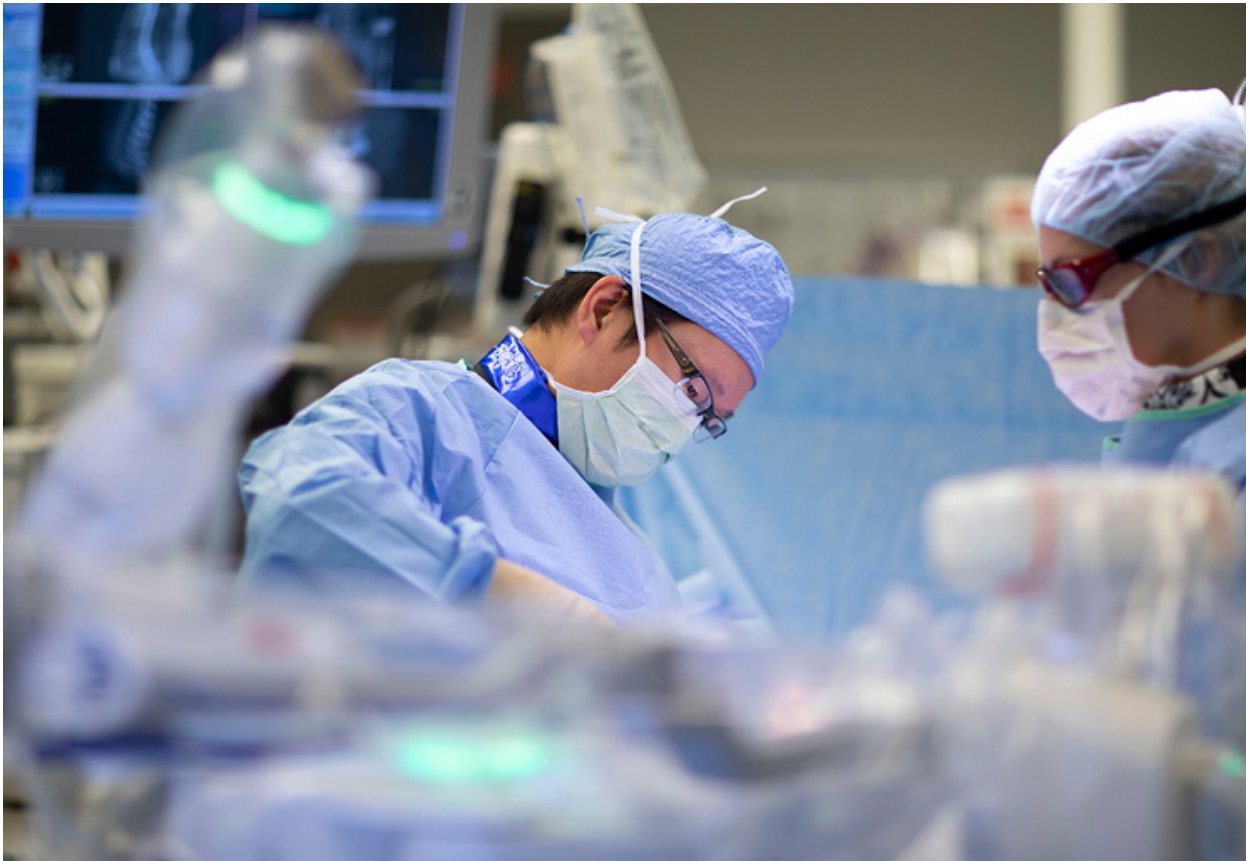Mayo Clinic has performed more than 200 robot-assisted spinal surgeries (Figure, see page 7), with positive early outcomes and declining procedural times.

“Robotics has given us options to treat patients more safely and effectively,” says Mohamad Bydon, M.D., a neurosurgeon at Mayo Clinic in Rochester, Minnesota.

Among 402 screws placed in 77 patients who had robot-assisted spinal surgery at Mayo Clinic, none required

postoperative revisions, according to a study published in the May 2021 issue of *Mayo Clinic Proceedings*. Two of the 402 screws required revision intraoperatively, and no complications related to screw placement were encountered in any of the patients studied.

“The robotic platform significantly enhances the accuracy of screw placement. It removes any human error that might be associated with fluoroscopically guided screw placement or even with stereotactic navigation,” says Selby



**Figure.** Selby G. Chen, M.D., a neurosurgeon at Mayo Clinic in Jacksonville, Florida, performs robot-assisted spinal surgery.

G. Chen, M.D., a neurosurgeon at Mayo Clinic in Jacksonville, Florida.

With the accrual of surgical experience, operative time declined significantly during the study period of Sept. 4, 2018, to Oct. 16, 2019. During that period the number of procedures performed per week increased.

“Although there is a learning curve with this technology, it is surmountable,” says Matthew T. Neal, M.D., a neurosurgeon at Mayo Clinic in Phoenix/Scottsdale, Arizona. “It is advantageous to develop comfort and familiarity with the technology at an early stage because we anticipate the robot will have increasing capabilities moving forward.”

The majority of robot-assisted spinal surgeries performed at Mayo Clinic are lumbar fusions and thoracolumbar fusions. Patients have preoperative and sometimes intraoperative CT imaging, which navigational software uses to help create a surgical plan. During surgery the software guides a robotic arm into position to ensure that the preoperative plan is accurately translated to trajectory guidance in the surgical field.

“As a result of the minimally invasive approach, patients have less pain and a lower need for pain medication,” Dr. Bydon says. The procedure can be performed with the patient awake or under anesthesia. Among patients in the Mayo Clinic study, the median length of hospitalization following the minimally invasive surgery was two days.

As an early adopter of robot-assisted technology, Mayo Clinic is able to look ahead to future applications. “We hope that as the technology advances, we will be able to apply it to the cervical spine as well as spinal decompression, disk preparation, the insertion of interbody cages and deformity correction,” Dr. Chen says.

Robot-assisted spinal surgery exemplifies Mayo Clinic’s patient-centered approach. “The accuracy and efficiency of the robot is part of our strategy to help reduce patients’ pain and enhance their recovery after spinal surgery, which are of the utmost importance to us,” Dr. Neal says.

**FOR MORE INFORMATION**

Bydon M, et al. Initiation of a robotic program in spinal surgery: Experience at a three-site medical center. *Mayo Clinic Proceedings*. 2021;96:1193.



Selby G. Chen, M.D.



Matthew T. Neal, M.D.

# Education 2022 Neurology and Neurologic Surgery Continuing Medical Education Programs

## FEBRUARY

Practical Neuroradiology: Excellence Through Evidence and Guidelines  
Feb. 13-17, 2022  
Four Seasons Resort and Residences, Whistler, British Columbia, Canada

Electromyography (EMG), Electroencephalography (EEG) & Neurophysiology in Clinical Practice — 2022  
Feb. 19-24, 2022  
Arizona State University (ASU) Health Futures Center, Phoenix

Mayo Clinic Advancements in Surgical & Medical Management of the Spine 2022  
Feb. 19-23, 2022  
Fairmont Orchid, Kohala Coast, Hawaii

## JUNE

Mayo Clinic Open and Endoscopic Techniques in Cranial Base Course  
June 1-4, 2022  
Mayo Clinic, Rochester, Minn.

## JULY

5th Annual Mayo Clinic Advances and Innovations in Complex Neuroscience Patient Care: Brain and Spine 2022  
July 27-30, 2022  
Enchantment Resort Sedona, Sedona, Arizona

## NOVEMBER

Neuroradiology: Practice to Innovation 2022  
Nov. 7-11, 2022  
The Ritz-Carlton, Grand Cayman, Seven Mile Beach, Grand Cayman, Cayman Islands

Parkinson's Disease and Other Movement Disorders 2022  
Nov. 11-12, 2022  
Mayo Clinic Franke Education Center, Phoenix

## INFORMATION AND REGISTRATION

**Mayo Clinic in Rochester, Minnesota**  
Phone: 800-323-2688 or 507-284-2509  
Email: [cme@mayo.edu](mailto:cme@mayo.edu)

**Mayo Clinic in Jacksonville, Florida**  
Phone: 800-462-9633 or 904-953-0421  
Email: [cme-jax@mayo.edu](mailto:cme-jax@mayo.edu)

**Mayo Clinic in Phoenix/Scottsdale, Arizona**  
Phone: 480-301-4580  
Email: [mca.cme@mayo.edu](mailto:mca.cme@mayo.edu)

Website: <https://ce.mayo.edu/neurology-and-neurologic-surgery>

## EXPEDITED PATIENT REFERRALS TO MAYO CLINIC DEPARTMENTS OF NEUROLOGY AND NEUROLOGIC SURGERY

While Mayo Clinic welcomes appointment requests for all neurologic and neurosurgical conditions, patients with the following conditions are offered expedited appointments:

- Cerebral aneurysms
- Cerebral or spinal arteriovenous malformations
- Brain, spinal cord or peripheral nerve tumors
- Epilepsy with indications for surgery
- Carotid disease



## Contact Us

Mayo Clinic welcomes inquiries and referrals, and a request to a specific physician is not required to refer a patient.

**Phoenix/Scottsdale, Arizona**  
844-292-8343

**Jacksonville, Florida**  
888-508-9912

**Rochester, Minnesota**  
844-627-7684



## Resources

***MayoClinic.org/medical-professionals***

Clinical trials, CME, Grand Rounds, scientific videos and online referrals

## Neurosciences Update

*Mayo Clinic Neurosciences Update* is written for physicians and should be relied upon for medical education purposes only. It does not provide a complete overview of the topics covered and should not replace the independent judgment of a physician about the appropriateness or risks of a procedure for a given patient.

### Medical Editors:

Laurence J. Eckel, M.D.  
Robert J. Spinner, M.D.  
Dean M. Wingerchuk, M.D.

### Editorial Board:

Bernard R. Bendok, M.D.  
Claudia F. Lucchinetti, M.D.  
James F. Meschia, M.D.  
Fredric B. Meyer, M.D.  
Alfredo Quinones-Hinojosa, M.D.

### Science Writer:

Barbara J. Toman

### Cover image:

Astrocytes and oligodendrocytes from neural stem cells. Credit: Yirui Sun

*Neurosciences Update* (MC5520-0921) is published by ©2021 Mayo Foundation for Medical Education and Research. All rights reserved. MAYO, MAYO CLINIC and the triple-shield Mayo logo are trademarks and service marks of MFMER. 200 First St. SW, Rochester, MN 55905. Periodicals postage paid at Rochester, Minn., and at additional mailing offices.