

# Neurosciences Update

Neurosciences News From Mayo Clinic Vol. 18, No. 5, 2021

NOVEMBER 2021

## In this issue

- 2 Focused Ultrasound: Incisionless Epilepsy Treatment
- 4 New Myelography Protocol Helps Localize CSF Leaks
- 5 Vestibular Schwannoma: Meeting Each Patient's Needs Through Shared Decision-Making

## Carotid Plaque Imaging: Updating the Management of Atherosclerotic Disease

Mayo Clinic uses state-of-the-art carotid plaque imaging to assess an individual's risk of stroke. Mayo's robust MRI protocols facilitate the detection of specific carotid plaque components associated with ischemic events, even in patients with minimal luminal stenosis.

"Not all plaques are alike. Carotid plaque imaging can help us determine — without invasive surgery — whether a patient's plaque is high risk or relatively stable and low risk," says John C. Benson, M.D., a neuroradiologist at Mayo Clinic in Rochester, Minnesota.

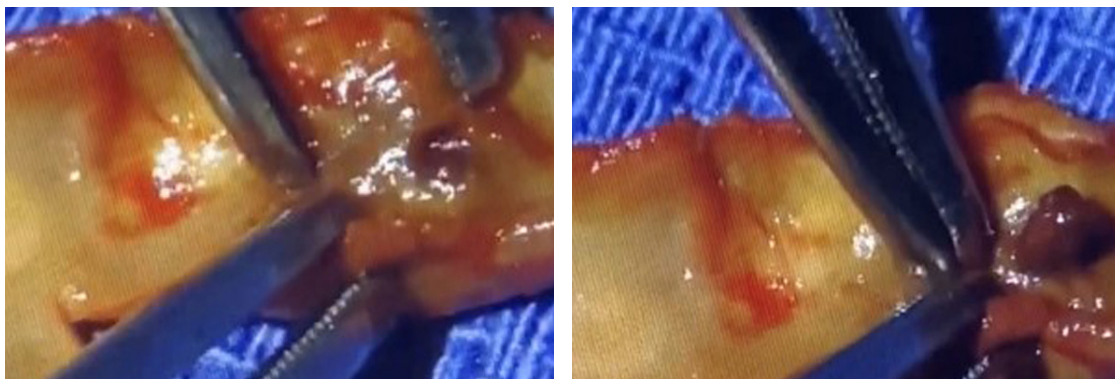
For 80 years, luminal stenosis of the carotid artery has been the primary prognosticator of ischemic events. Since the 1990s, the standard threshold for intervention has been 50% stenosis.

But over the past decade, attention has turned to patients with mild or moderate

carotid stenosis who nonetheless have strokes. As a result, interest in various carotid plaque components (Figure), including intraplaque hemorrhage, has grown.

"As many as 20% to 30% of stroke patients may have intraplaque hemorrhage. That is hundreds of thousands of patients a year," says Luis E. Savastano, M.D., Ph.D., a cerebrovascular neurosurgeon at Mayo Clinic in Rochester, Minnesota. "At Mayo, we have developed an MRI protocol that can detect intraplaque hemorrhage. Knowing whether a patient has a biomarker of plaque vulnerability allows us to select the patients that are most likely to benefit from intervention, such as stenting or carotid endarterectomy."

A Mayo Clinic study published in the July 2021 issue of *American Journal of Neuroradiology* found that intraplaque hemorrhage is independently associated with ischemic events in carotid arteries with



**Figure.** On the left, photograph of a surgical specimen shows an ulcerated plaque in the arterial surface between the forceps. On the right, mild pressure on the plaque results in an intraplaque hematoma protruding through the ulceration into the arterial lumen.



John C. Benson, M.D.

less than 30% stenosis. An earlier study — published in the February 2021 issue of *JACC: Cardiovascular Imaging* — reported a higher rate of recurrent stroke in patients who had embolic stroke of undetermined source (ESUS) with associated intraplaque hemorrhage compared with patients with ESUS with no associated intraplaque hemorrhage.

Mayo Clinic researchers are planning a clinical trial to assess the use of carotid plaque imaging to detect intraplaque hemorrhage and to stratify patients' risk of stroke.

### 'LIKE A MICROSCOPIC VIEW OF PLAQUE COMPOSITION'

Approximately 25% of individuals who have strokes have a diagnosis of cryptogenic stroke after full medical workup. Computerized tomography angiography (CTA), a standard component of acute stroke imaging, has significant limitations.

"CTA can show the degree of carotid stenosis and provide some sense of the nature of the plaque. But CTA can't differentiate the lipid-rich necrotic core from the superimposed hemorrhage that sometimes exists," Dr. Benson says.

Mayo Clinic uses magnetization prepared rapid acquisition gradient echo (MPRAGE) to perform carotid plaque imaging. This level of technology, and the expertise needed to analyze MPRAGE imaging, contribute to Mayo Clinic's successful use of carotid plaque imaging.

"It's almost like having a microscopic view of the plaque composition," says Michelle P. Lin, M.D., M.P.H., a vascular neurologist at Mayo Clinic in Jacksonville, Florida. "More often than not, carotid plaque imaging confirms our clinical suspicion that a patient has unstable plaque."

By helping to identify the root cause of a stroke, carotid plaque imaging can prevent unnecessary and frequently unrevealing diagnostic tests. "Understanding why they are having strokes also provides peace of

mind to patients," Dr. Savastano says. In addition, carotid plaque imaging allows the clinical team to appropriately target the therapy that is most likely to prevent stroke recurrence. Mayo Clinic's vascular neurology and neurosurgery group has published the largest series to date of carotid revascularizations in patients experiencing strokes who had nonstenotic carotid arteries with plaque hemorrhage detected by carotid plaque imaging. Despite receiving maximal medical therapy, more than 70% of those patients had experienced multiple recurrent strokes but had no additional strokes after surgery.

In addition to guiding decisions about stenting or endarterectomy, carotid plaque imaging can help determine medical treatment. "Patients with a diagnosis of cryptogenic stroke might just be given aspirin. But if we know the stroke is caused by unstable carotid plaque, then we might prescribe a higher intensity anti-thrombotic regimen for plaque stabilization, or even referral to our surgical colleagues for revascularization," Dr. Lin says. "As a diagnostic tool, carotid plaque imaging brings a lot of value to patient care."

Mayo Clinic has a distinguished history of innovation in the diagnosis and treatment of carotid artery disease. "Carotid plaque imaging is overturning the dogma that 50% stenosis is necessary before intervention," Dr. Savastano says. "This imaging has the potential to change the ways we think about this disease and manage patients."


### FOR MORE INFORMATION

Larson AS, et al. Carotid intraplaque hemorrhage and stenosis: At what stage of plaque progression does intraplaque hemorrhage occur, and when is it most likely to be associated with symptoms? *American Journal of Neuroradiology*. 2021;42:1285.

Larson AS, et al. Embolic stroke of undetermined source: The association with carotid intraplaque hemorrhage. *JACC: Cardiovascular Imaging*. 2021;14:506.



Luis E. Savastano, M.D., Ph.D.



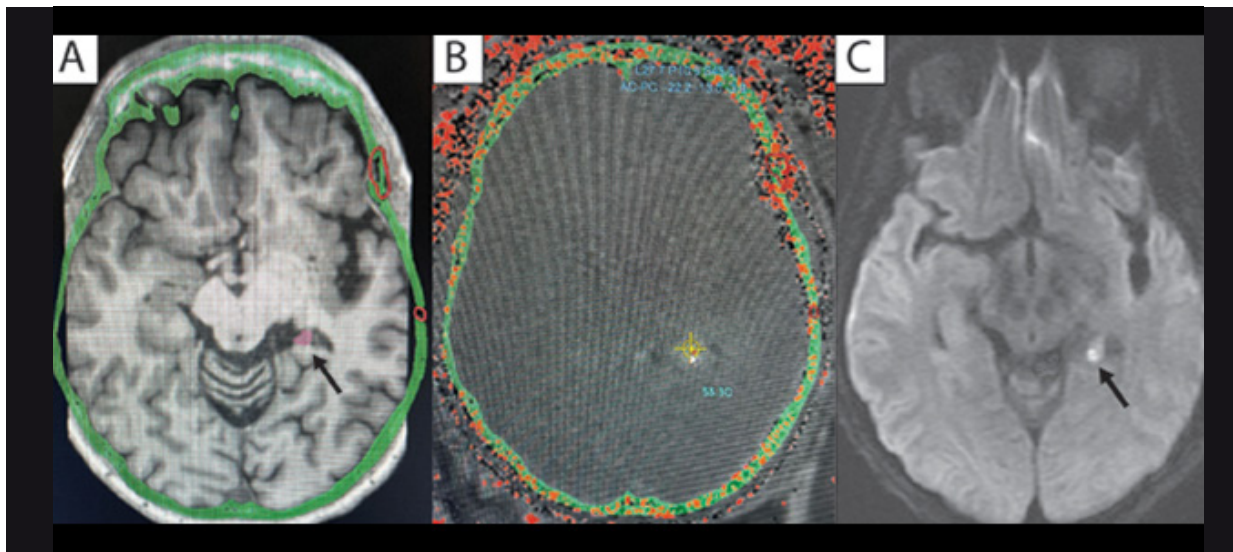
Michelle P. Lin, M.D., M.P.H.

## Focused Ultrasound: Incisionless Epilepsy Treatment

Mayo Clinic is investigating the use of magnetic resonance (MR)-guided focused ultrasound as an incisionless treatment for medication-refractory focal epilepsy. The thermoablative therapy has the potential

to reduce or eliminate seizures for individuals whose epilepsy doesn't respond to medication without requiring any drilling through the skull.





**Figure.** A. Pre-procedural imaging known as magnetization prepared rapid acquisition gradient echo (MPRAGE) registered to CT shows the calvarium (green) with a prior craniotomy (red) marked as a no-pass zone for ultrasound. The hippocampal tail remnant is outlined in magenta (black arrow). B. Intraprocedural MR thermometry shows the hippocampal tail target (yellow circle and crosshairs). C. Immediate post-procedural diffusion-weighted imaging shows the ablated hippocampal tail with bright signal (black arrow).

“The focused ultrasound energy kills highly selected areas that we can select on imaging — disrupting the epilepsy network without surgical resection of the lesion,” says Jamie J. Van Gompel, M.D., a neurosurgeon at Mayo Clinic in Rochester, Minnesota. “Our hope is eventually to make many of these patients seizure-free without ever having to make an incision.”

MR-guided focused ultrasound has been used to treat movement disorders, such as essential tremor. Mayo Clinic’s study of the technology for the treatment of focal epilepsy is part of a multicenter clinical trial. Patient enrollment in the trial is by invitation only.

The technology focuses ultrasound waves through the skull to treat deep areas of the brain. MR guidance helps identify and target the tissue to be permanently treated and tracks the treatment in real time.

Mayo Clinic’s first trial participant recently had MR-guided focused ultrasound ablation in a hippocampal remnant that remained after temporal lobectomy (Figure). “The patient has had a substantial reduction in seizures and is very happy with the results thus far,” Dr. Van Gompel says.

He notes that MR-guided focused ultrasound potentially might be used to perform:

- Hippocampal disconnection, to prevent seizure outflow from the temporal lobe to the rest of the brain
- Thalamic ablation, for patients who previously responded to procedures that stimulated the anterior nucleus of the thalamus
- Ablation of hypothalamic hamartomas
- Ablation of cortical dysplasias

### NEURORADIOLOGIC EXPERTISE

About one-third of people with epilepsy have medically refractory seizures. In the past, treatment relied on surgical removal of lesions in areas such as the temporal or frontal lobe or insular cortex.

Incisionless treatments require expert imaging to locate seizure-origin sites and to guide the performance of these interventions. Mayo Clinic’s radiologists have extensive experience with ablative treatments elsewhere in the body and helped guide the adoption of those technologies for use in the brain.

“We have partnered with our neurosurgeons from the beginning of laser and focused ultrasound treatments in the brain,” says Timothy J. Kaufmann, M.D., M.S., a neuroradiologist at Mayo Clinic’s Rochester campus. “Our experience with focused ultrasound thalamotomy has shown us that we can be very precise with our imaging and use of the ablation device.”

Dr. Kaufmann notes that current technology limits the use of MR-guided focused ultrasound to lesions relatively close to the midline.

“Because of the geometry and physics of the device, those are the areas where we can raise temperatures to a therapeutic level and induce ablation. However, recent experimental advances in the focused ultrasound equipment have extended the reach of this device to a degree,” he says. “Small lesions also might be more suited to this treatment because it would take too much time to treat very large lesions, and the efficiency of brain heating diminishes over the course of an ablation.”



Jamie J. Van Gompel, M.D.



Timothy J. Kaufmann, M.D., M.S.

The investigation of MR-guided focused ultrasound is part of Mayo Clinic's commitment to providing the least invasive care that will be effective for patients with refractory epilepsy. "We work on a variety of platforms to treat epilepsy without large cranial incisions," Dr. Van Gompel says. "Collaboration with our colleagues

in Neuroradiology is critical to providing these treatment options for our patients."

#### FOR MORE INFORMATION

InSightec. MR-Guided Focused Ultrasound in the Treatment of Focal Epilepsy (EP001). [ClinicalTrials.gov](https://ClinicalTrials.gov).

## New Myelography Protocol Helps Localize CSF Leaks



Carrie M. Carr, M.D.

Mayo Clinic's use of state-of-the-art myelography facilitates the localization of even tiny cerebrospinal fluid (CSF) leaks. A key tool, used since 2018, is lateral decubitus digital subtraction myelography (DSM).

"Before you can treat a CSF leak, you have to find it. And that can be very tricky," says Carrie M. Carr, M.D., a neuroradiologist and chair of neuroradiology procedures at Mayo Clinic in Rochester, Minnesota. "Often the leak is small and subtle, but even a large leak can be quite difficult to image."

Lateral decubitus DSM is part of Mayo Clinic's new imaging protocol for patients who present with spontaneous intracranial hypotension. That protocol starts with:

- High-resolution brain MRI, which can measure abnormalities down to the millimeter
- High-resolution spinal MRI, which can detect even very small areas of extradural fluid

"Each of these successive steps is important," Dr. Carr says. "A standard spine MRI, without these specialized techniques, often can't tell us what type of myelogram would best find the precise location of the leak."

Spinal CSF leaks can cause debilitating symptoms. "Most patients I see are completely miserable. They are missing work and important life activities because of orthostatic headaches and other manifestations of CSF leaks," says Jeremy K. Cutsforth-Gregory, M.D., a neurologist and director of the CSF dynamics clinic at Mayo Clinic's campus in Rochester. "Many patients are rendered bedbound, but effective treatment is often available once the leak is found."

#### HIGH DIAGNOSTIC YIELD

At Mayo Clinic, specific findings on brain and spinal MRI guide decisions about subsequent myelography. Hyperdynamic CT myelogram

is used when a herniated disk or an osteophyte appears to have caused a rent in the dura and CSF leak. Lateral decubitus DSM is used when a CSF-venous fistula or nerve root sleeve tear is suspected.

Lateral decubitus DSM at Mayo Clinic has a high diagnostic yield for finding the exact location of a CSF leak. A retrospective study published in the March 2, 2021, issue of *Neurology* found that 53.2% of patients investigated for spontaneous intracranial hypotension at Mayo Clinic had a CSF leak identified on lateral decubitus DSM.

Dr. Carr notes that DSM can yield varying results, depending on the techniques used. She cites a recent patient who came to Mayo Clinic after DSM at another major center didn't detect a CSF leak.

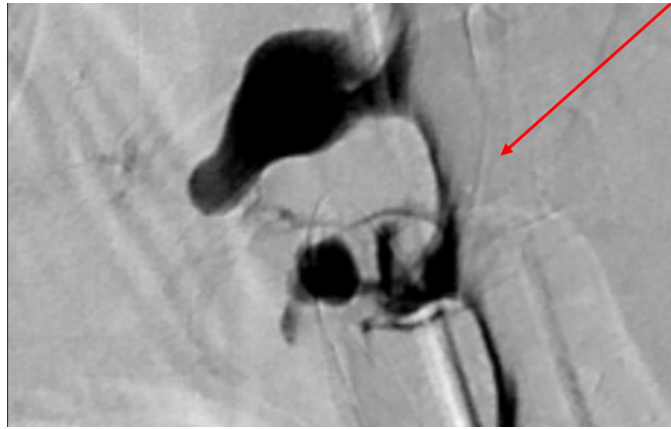
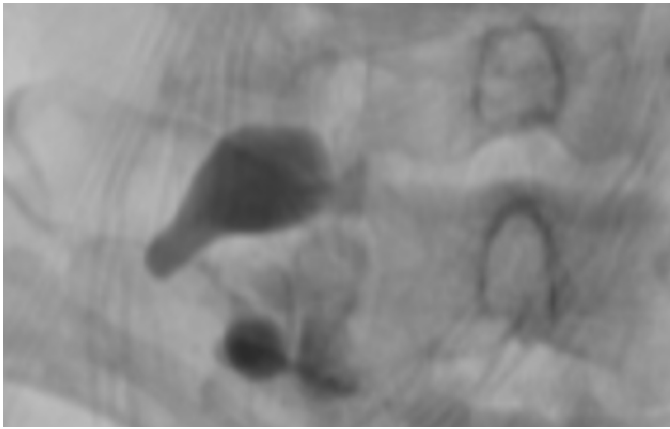
"We performed our lateral decubitus DSM protocol and found a very large CSF-venous fistula," Dr. Carr says (Figure, see page 5). "A lot of highly specialized work has gone into perfecting our technique."

Mayo Clinic routinely performs bilateral DSM testing to evaluate both sides of the spine, as the presence of leak can be bilateral, though this is rare. The testing is performed over two days due to limits on the amount of contrast dye that can be injected. A succession of fluoroscopic images is taken, with any constant aspects of the successive images subtracted from the original.

"That helps us to detect change," Dr. Carr says. "Contrast flows into the fistula, opacifying the connection between the thecal sac and the abnormal connection to veins. These blood vessels are tiny, and the contrast can flicker, making it difficult to visualize. The digital subtraction technique makes these CSF-venous fistulas more conspicuous."



Jeremy K. Cutsforth-Gregory, M.D.



**Figure.** Images illustrate the diagnosis of a 61-year-old woman presenting with abrupt onset of Valsalva-related headache. The patient subsequently experienced tinnitus, muffled hearing and constant daily headache. On the left, DSM performed at a major center shows no visible venous structures around the abnormal nerve sheath diverticulum. On the right DSM performed at Mayo Clinic shows a large complex CSF-venous fistula (red arrow) at the same location.

Treatment of spinal CSF leaks and CSF-venous fistulas typically involves spinal surgery, paraspinous vein embolization, epidural blood patch or fibrin glue injection. Determining the optimal treatment for each patient requires definitive localization and characterization of the leak.

“Surgery and embolization — the most definitive treatments — are only possible when the precise site of a leak is known,” Dr. Cutsforth-Gregory says. “Epidural blood patch and fibrin glue can be applied in a non-targeted fashion but are much more effective when performed at the precise site of leakage. Adding CT guidance during patching enhances safety, as the needles — and thus the blood or fibrin — are directed closer to the nerve roots and the ventral aspect of the

spinal cord. The close collaboration between neurologists and neuroradiologists at Mayo Clinic allows us to tailor the treatment to the clinical circumstances.”

Mayo Clinic’s distinguished history of imaging expertise is a cornerstone of Mayo’s ability to manage CSF leaks. “We always put the patient first, and the practice supports innovation,” Dr. Carr says. “We are willing to invest time and effort to successfully detect and treat CSF leaks.”

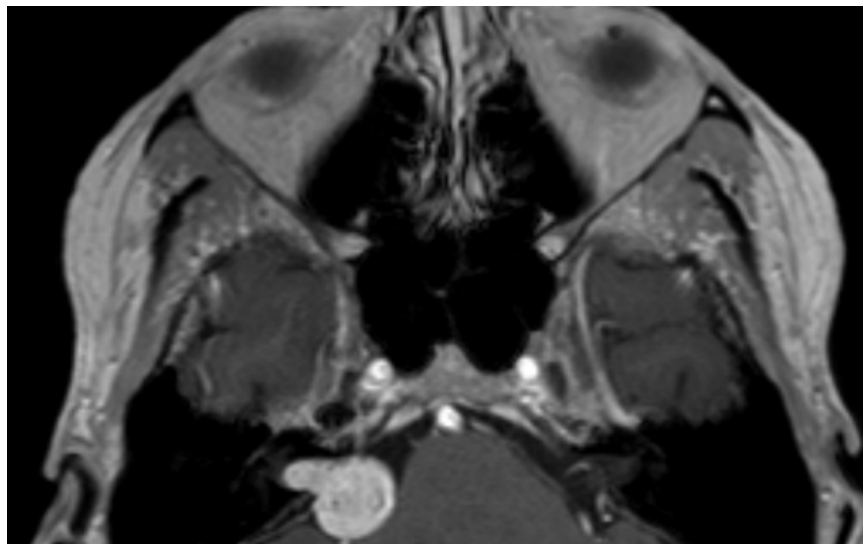
**FOR MORE INFORMATION**

Kim DK, et al. Diagnostic yield of lateral decubitus digital subtraction myelogram stratified by brain MRI findings. *Neurology*. 2021;96:e1312.

## Vestibular Schwannoma: Meeting Each Patient’s Needs Through Shared Decision-Making

Vestibular schwannomas are often considered rare, yet their prevalence is rising due to sensitive diagnostic imaging. The clinical behavior of these intracranial tumors is unpredictable, complicating decisions about optimal management. Mayo Clinic has a large-volume practice in vestibular schwannomas (Figure) and multidisciplinary specialists with experience in all treatment options.

“Vestibular schwannomas have been the focus of our lateral skull base team for more than 20 years. We’ve dedicated our careers to treating these patients and have become national and international experts,” says Michael J. Link, M.D., a neurosurgeon at Mayo Clinic in Rochester, Minnesota.



**Figure.** Contrast-enhanced axial T1-weighted MRI of the head reveals a medium-sized, right-sided cerebello-pontine angle tumor that is consistent with a vestibular schwannoma.





Michael J. Link, M.D.

A neurosurgeon and an otolaryngologist meet jointly with each patient to assess the person’s imaging, discuss treatment and achieve consensus on the best approach: observation, microsurgery or radiosurgery.

“All three treatments have merit, and we use them with relatively equal frequency. We don’t have strong bias toward one particular treatment,” says Matthew L. Carlson, M.D., an otolaryngologist at Mayo Clinic in Rochester, Minnesota.

In a review published in the April 8, 2021, edition of the *New England Journal of Medicine*, Drs. Carlson and Link noted the recent shift toward conservative management strategies that preserve hearing and quality of life for patients with sporadic vestibular schwannomas. Quality of life is a major focus of vestibular schwannoma research at Mayo Clinic.

“Data show that the diagnosis itself and various patient-related factors often affect quality of life more than treatment choice does,” Dr. Carlson says. “Achieving the best quality of life means looking at all these patient-specific factors to provide the best treatment for each individual.”



Matthew L. Carlson, M.D.

### EXPERTISE IN ALL TREATMENT APPROACHES

Up to 25% of new vestibular schwannomas are identified incidentally during imaging that was obtained for unrelated indications. The tumors may be just millimeters in diameter. “Because MRI is now so widely available, vestibular schwannomas are often discovered when they’re small and minimally symptomatic or asymptomatic,” Dr. Link says.

Patients who are experiencing signs and symptoms might present with dizziness, imbalance, unilateral hearing loss or tinnitus. Large tumors can cause facial numbness or headaches due to hydrocephalus.

Mayo Clinic’s multidisciplinary vestibular schwannoma team includes neurosurgeons and otolaryngologists as well as audiologists and physical therapists. Comprehensive vestibular evaluation is available.

“Our approach involves taking the time to meet as a team with patients and discuss the pros and cons of each treatment option for that individual,” Dr. Link says. “We almost always recommend surgically removing large or very fast-growing tumors.

But vestibular schwannomas are often growing slowly or not at all, so observation is an option for many patients with small or medium-sized tumors.”

For patients who choose observation, Mayo Clinic recommends imaging and audiologic evaluation six months after the initial diagnosis. If the tumor isn’t growing, imaging and hearing evaluations are performed annually for five years and possibly every two years after that. Lifelong follow-up is needed because vestibular schwannomas can undergo saltatory or delayed growth.

Some patients with smaller vestibular schwannomas prefer treatment over initial observation. “Just having a tumor in the head can create a lot of anxiety in some cases,” Dr. Carlson says. “Preserving a patient’s quality of life requires decision-making to center on the patient’s goals and priorities.”

When treatment is indicated, microsurgery is generally used to resect large vestibular schwannomas. The procedure requires the use of an operative microscope with intraoperative neural monitoring.

Although serviceable hearing is preserved after microsurgery in up to 70% of patients with small tumors, the rate is less than 5% after microsurgical removal of large tumors. Total resection of a large tumor also has a moderate risk of facial nerve paralysis. To avoid those complications, surgeons might leave a tumor remnant around the facial nerve and brainstem.

Radiosurgery is generally an option for tumors that measure less than 2.5 centimeters in diameter. Mayo Clinic’s preferred mode of radiosurgery for treating vestibular schwannomas is Gamma Knife stereotactic radiosurgery. An early adopter of this technology, Mayo Clinic has performed Gamma Knife stereotactic radiosurgery for more than 30 years for nearly 10,000 patients.

“We have a great deal of experience and expertise in radiosurgery, and in microsurgery and the wait-and-scan approach,” Dr. Link says. “As a result, patient preference can play a major role in our decision-making.”

### FOR MORE INFORMATION

Carlson ML, et al. Vestibular schwannomas. *New England Journal of Medicine*. 2021;384:1335.

# Research Highlights in Neurology and Neurosurgery

## EARLY IMAGING BIOMARKER FOR LEWY BODY DISEASE

Neurodegeneration of the substantia nigra in Lewy body disease is associated with iron deposition. Quantitative susceptibility mapping (QSM) provides in vivo estimation of regional iron deposition by reconstructing magnetic susceptibility sources from field perturbation. Although QSM is sensitive for brain iron content in several neurodegenerative diseases, little is known about QSM findings in patients on the dementia with Lewy bodies (DLB) spectrum, especially during the prodromal stage of disease. Mayo Clinic researchers have demonstrated that QSM can identify increased magnetic susceptibility in the substantia nigra in patients with probable and prodromal DLB. Study participants were divided into four groups: patients with idiopathic rapid eye movement sleep behavior disorder (iRBD), which is an early feature of evolving DLB; patients with prodromal DLB; patients with probable DLB; and a clinically unimpaired control group. Each participant had QSM, and the groups were compared. The researchers found that patients with probable DLB had higher susceptibility in the substantia nigra compared with the control group and patients with prodromal DLB. The susceptibility of the substantia nigra showed an increasing trend from controls to the iRBD group to the prodromal DLB group to the probable DLB group. Parkinsonism severity wasn't associated with the mean susceptibility in the substantia nigra in the patient groups. The data suggest that QSM is a potential early biomarker for DLB. In addition, the trend of increasing susceptibility in the study groups suggests that iron deposition starts to rise early in the Lewy body disease process and independently of parkinsonism severity. The researchers note that understanding the evolution of iron dysregulation in the substantia nigra is important for potential disease-modifying therapies targeting early stages of DLB. (Chen Q, et al. MRI quantitative susceptibility mapping of the substantia nigra as an early biomarker for Lewy body disease. *Journal of Neuroimaging*. 2021;31:1020.)

## NOVEL TECHNIQUE FOR AWAKE SPINAL SURGERY

Transforaminal lumbar interbody fusion (TLIF) is a surgical technique to address lumbar radiculopathy due to several pathologies, including spondylolisthesis and foraminal stenosis. Interest has grown in the use of minimally invasive techniques and regional anesthesia for this surgery. Mayo Clinic researchers have described a novel technique to perform minimally invasive awake TLIF using a pedicle-based retraction system, as well as factors to consider to safely perform awake spinal surgery. The researchers found that a pedicle-based distraction allows easier access to the intervertebral disk space for both disk preparation and cage placement. The researchers note that the first 10 awake procedures performed with the technique had a mean procedure time of 117.3 minutes and a mean total time in the operating room of 151 minutes. No surgery was converted to general anesthesia, and no intraoperative complications were reported. (De Biase G, et al. Awake minimally invasive transforaminal lumbar interbody fusion with a pedicle-based retraction system. *Clinical Neurology and Neurosurgery*. 2021;200:106313.)

## DEFINING THE PATHOBIOLOGY OF PROGRESSIVE APRAXIA OF SPEECH

Progressive apraxia of speech (PAOS) is a neurodegenerative syndrome affecting spoken communication that eventually results in mutism. The condition also typically evolves into a Parkinson-plus syndrome, with features such as bradykinesia and rigidity but not tremor. Although four-repeat (4R) tauopathy has been considered a possible underlying pathology, PAOS has yet to be fully elucidated. Mayo Clinic has reported results from a study of 32 patients with autopsy-confirmed PAOS who were followed over 10 years. Molecular pathology, biochemistry, genetics and longitudinal imaging were investigated in the prospectively recruited cohort. Perceptually distinct speech characteristics, combined with age at onset, predicted specific 4R-tauopathy: The phonetic subtype of PAOS and younger age predicted corticobasal degeneration, and the prosodic subtype and older age predicted progressive supranuclear palsy. Patients with corticobasal degeneration had faster rates of decline, greater cortical degeneration and shorter duration of illness than patients with progressive supranuclear palsy. The phonetic and prosodic subtypes showed differing relationships within the cortico-striato-pallido-nigro-luysial network. The researchers note that their findings may have consequences for the development of PAOS treatments that target 4R-tauopathy. (Josephs KA, et al. A molecular pathology, neurobiology, biochemical, genetic and neuroimaging study of progressive apraxia of speech. *Nature Communications*. 2021;12:3452.)

# Education 2022 Neurology and Neurologic Surgery Continuing Medical Education Programs

## FEBRUARY

### Practical Neuroradiology: Excellence Through Evidence and Guidelines

Feb. 13-17, 2022

Four Seasons Resort and Residences, Whistler, BC, Canada

### Electromyography (EMG), Electroencephalography (EEG) & Neurophysiology in Clinical Practice — 2022

Feb. 19-24, 2022

Arizona State University (ASU) Health Futures Center, Phoenix

### Mayo Clinic Advancements in Surgical & Medical Management of the Spine 2022

Feb. 19-23, 2022

Fairmont Orchid, Kohala Coast, Hawaii

## JUNE

### Mayo Clinic Open and Endoscopic Techniques in Cranial Base Surgery Course

June 1-4, 2022

Mayo Clinic, Rochester, Minn.

## JULY

### Neurology in Clinical Practice 2022

July 14-17, 2022

Lowes Coronado Bay Resort, Coronado, Calif.

### 5th Annual Mayo Clinic Advances and Innovations in Complex Neuroscience Patient Care: Brain and Spine 2022

July 27-30, 2022

Enchantment Resort Sedona, Sedona, Ariz.

## NOVEMBER

### Parkinson's Disease and Other Movement Disorders 2022

Nov. 4-5, 2022

Arizona State University (ASU) Health Futures Center, Phoenix

### Neuroradiology: Practice to Innovation 2022

Nov. 7-11, 2022

The Ritz-Carlton, Grand Cayman, Seven Mile Beach, Grand Cayman, Cayman Islands

## INFORMATION AND REGISTRATION

### Mayo Clinic in Rochester, Minnesota

Phone: 800-323-2688 or 507-284-2509

Email: [cme@mayo.edu](mailto:cme@mayo.edu)

### Mayo Clinic in Jacksonville, Florida

Phone: 800-462-9633 or 904-953-0421

Email: [cme-jax@mayo.edu](mailto:cme-jax@mayo.edu)

### Mayo Clinic in Phoenix/Scottsdale, Arizona

Phone: 480-301-4580

Email: [mca.cme@mayo.edu](mailto:mca.cme@mayo.edu)

Website: <https://ce.mayo.edu/neurology-and-neurologic-surgery>



## Contact Us

Mayo Clinic welcomes inquiries and referrals, and a request to a specific physician is not required to refer a patient.

### Phoenix/Scottsdale, Arizona

844-292-8343

### Jacksonville, Florida

888-508-9912

### Rochester, Minnesota

844-627-7684



## Resources

### [MayoClinic.org/medical-professionals](https://www.mayoclinic.org/medical-professionals)

Clinical trials, CME, Grand Rounds, scientific videos and online referrals

## Neurosciences Update

*Mayo Clinic Neurosciences Update* is written for physicians and should be relied upon for medical education purposes only. It does not provide a complete overview of the topics covered and should not replace the independent judgment of a physician about the appropriateness or risks of a procedure for a given patient.

### Medical Editors:

Laurence J. Eckel, M.D.

Robert J. Spinner, M.D.

Dean M. Wingerchuk, M.D.

### Editorial Board:

Bernard R. Bendok, M.D.

Claudia F. Lucchinetti, M.D.

James F. Meschia, M.D.

Fredric B. Meyer, M.D.

Alfredo Quinones-Hinojosa, M.D.

### Science Writer:

Barbara J. Toman

### Cover image:

Astrocytes and oligodendrocytes from neural stem cells. Credit: Yirui Sun

*Neurosciences Update* (MC5520-1221) is published by ©2021 Mayo Foundation for Medical Education and Research. All rights reserved. MAYO, MAYO CLINIC and the triple-shield Mayo logo are trademarks and service marks of MFMER. 200 First St. SW, Rochester, MN 55905. Periodicals postage paid at Rochester, Minn., and at additional mailing offices.

## EXPEDITED PATIENT REFERRALS TO MAYO CLINIC DEPARTMENTS OF NEUROLOGY AND NEUROLOGIC SURGERY

While Mayo Clinic welcomes appointment requests for all neurologic and neurosurgical conditions, patients with the following conditions are offered expedited appointments:

- Cerebral aneurysms
- Cerebral or spinal arteriovenous malformations
- Brain, spinal cord or peripheral nerve tumors
- Epilepsy with indications for surgery
- Carotid disease