

## Imaging aids removal of aspirated dental crown

By Melissa Busch, DrBicuspid.com associate editor

June 22, 2021 -- A chest x-ray helped identify a 9.5-mm dental crown discovered in the lung of an 81-year-old man admitted to the hospital for meningitis. The international team of authors behind the case published their report in the August issue of *Radiology Case Reports*.

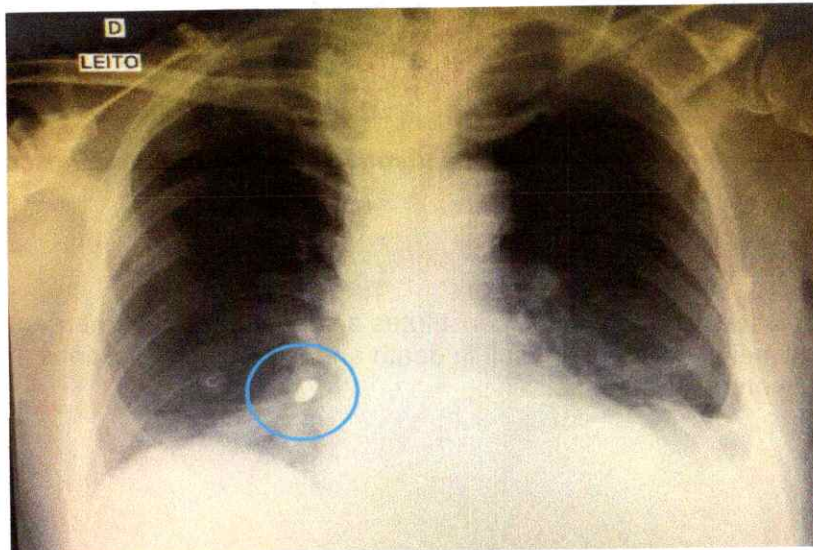
ADVERTISEMENT



**IT'S ALL IN THE BOX**  
It's like having an entire IT team in the box. **ONE | TechCentral**  
[FIND OUT MORE](#)

Patients with respiratory alterations or who appear to have missing dental elements or loosening teeth following an accident or emergency should undergo imaging to prevent serious complications, the authors wrote. This is especially true for older patients, who often experience deterioration in oral hygiene and caries. Dentists should be mindful of the treatment options for these patients, they noted.

"Careful creation, placement, maintenance, and preservation of prosthetic crowns are critically important in elderly patients," wrote the group, led by Dr. Henrique Hadad from the oral and maxillofacial surgery department at the São Paulo State University School of Dentistry in Araçatuba, Brazil (*Radiol Case Rep*, August 2021, Vol. 16:8, pp. 2280-2285).



*A chest x-ray revealed a foreign body, eventually identified as a dental crown, in a man's right lower lobe bronchus. All images courtesy of Hadad et al. Licensed under [CC BY-NC-ND 4.0](#).*

### Emergency situation

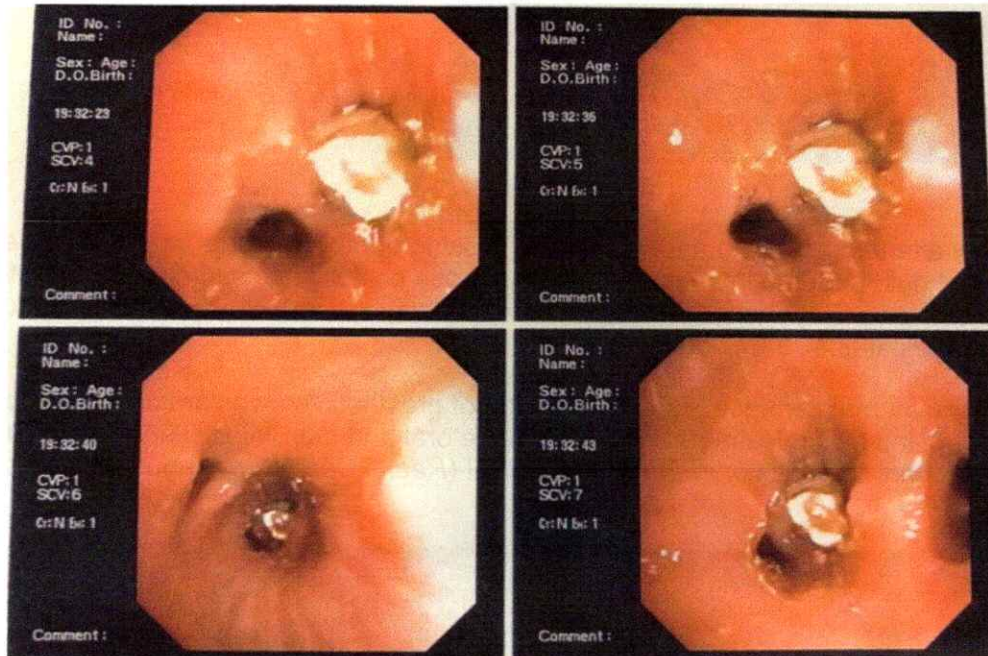
The case report focused on an 81-year-old man admitted to an intensive care unit for meningitis. The patient experienced altered consciousness and his oxygen saturation dropped, resulting in him needing emergency orotracheal intubation.

After the tube was placed, the patient underwent a chest x-ray to ensure the tube was in the proper location. However, imaging also revealed a foreign body shaped like a dental prosthetic crown in his right lower lobe bronchus.

Clinicians then assessed the patient's bronchus using an orotracheal intubation cannula along with a flexible bronchoscope and basket clamp. They chose this method because it has a lower risk of morbidity and mortality, the authors noted.

The scope passed freely through the patient's trachea without alteration of its caliber and without causing mucosal lesions. Using the scope, the team visualized the dental crown, which was obliterating the man's lower lobe bronchus in his right lung.


Clinicians used the basket clamp to grab the upper premolar dental prosthetic crown and then used the cannula to remove it. The procedure was completed without complications, and the patient was reintubated. Approximately one hour passed from the time the clinicians identified the tooth until its removal.



*Image of aspirated dental crown captured using a flexible bronchoscope and clamp.*

### Managing a difficult case

Though crown aspiration is relatively uncommon, it constitutes a serious medical emergency, the authors wrote. Failure to remove the prosthetic in a timely fashion can result in death and severe complications, including aspiration pneumonia or obstructive pulmonary abscesses.



*The removed 9.5-mm prosthetic dental crown.*

Multiple factors are linked to loosening or fractured dental crowns, including caries, poor oral hygiene, cement types, periodontal disease, and poor prosthetic planning. Care should be taken when performing intubations or other such procedures on elderly patients, according to the authors.

Though following all recommendations while handling trauma or emergency patients is not always feasible, prevention is the best route to avoiding accidental ingestion or aspiration of dental prosthesis. Nevertheless, imaging is a vital component of diagnosing and treating patients who may have ingested or aspirated a foreign object, the authors added.

"Effective diagnosis is important to prevent further complications in patients who aspirate prosthetic dental crowns," Hadad and colleagues wrote.

♥ [If you like this content, please share it with a colleague!](#)

Copyright © 2021 DrBicuspid.com

Last Updated np 6/21/2021 5:14:24 PM

## Forum Comments

[Post your comment ...](#)

## Orthodontic wire leads to appendicitis in 11-year-old girl

By Melissa Busch, DrBicuspid.com associate editor

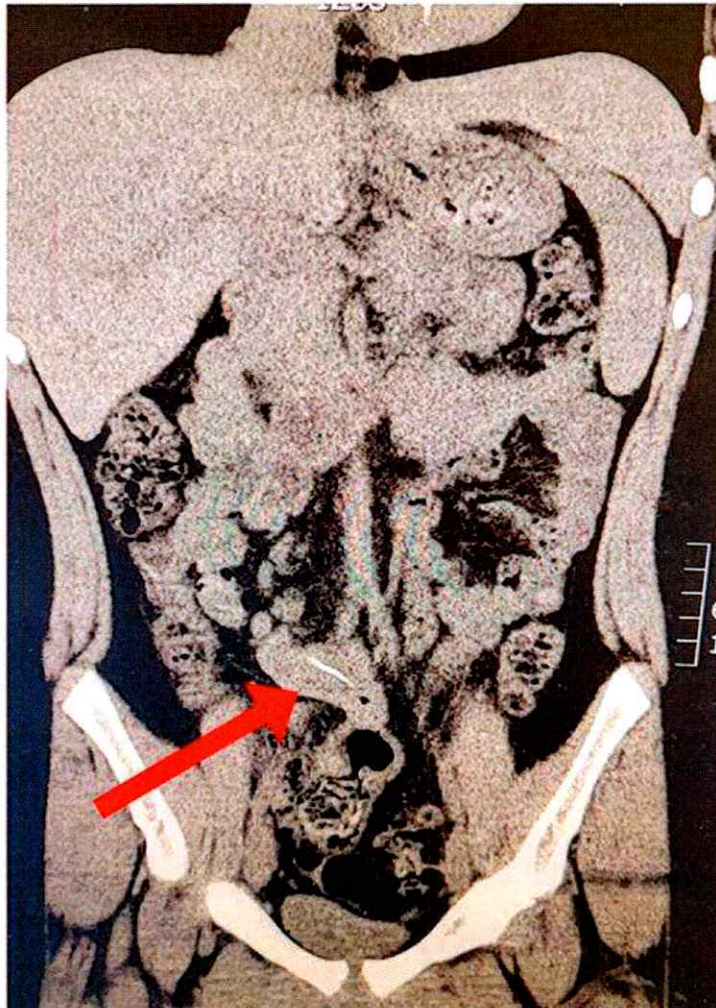
June 7, 2021 -- A 2.7-cm orthodontic wire caused appendicitis in an 11-year-old girl in California, according to a report published in the August issue of the *Journal of Pediatric Surgery Case Reports*. The girl, who unknowingly swallowed the wire, is believed to be the first case of dental hardware being dislodged and causing appendicitis in a child.

ADVERTISEMENT



**IT'S ALL IN THE BOX**  
It's like having an entire IT team in the box. **ONE** TechCentral  
[FIND OUT MORE](#)

Imaging revealed the wire and helped clinicians make the diagnosis. The case highlights the importance of promptly moving forward with appropriate treatment when imaging reveals a radiolucent object in the appendix, the authors wrote.



Computed tomography (CT) scan shows a 2.7-cm linear object in the girl's terminal ileum. All images courtesy of Sacks et al. Licensed under [CC BY-NC 4.0](#).

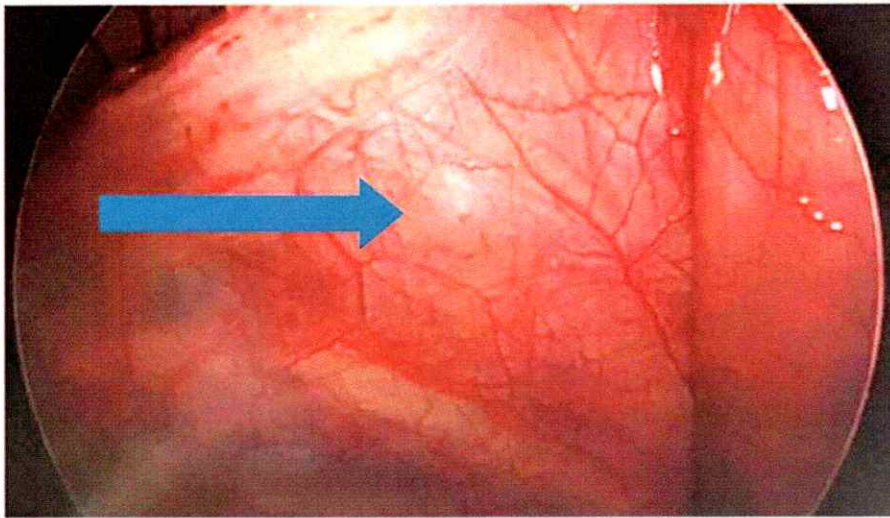
"Braces are a common phase in children and young adults, so it's possible to conceive the idea that bands, brackets, or wires may become broken or dislodged and ingested, but they have never been reported to cause appendicitis," wrote the group, led by Dr. Marla Sacks from Loma Linda University Children's Hospital in Loma Linda, CA (*J Pediatr Surg Case Rep*, Vol. 71, 101909).

### Unusual circumstances

After three days of abdominal pain, the 11-year-old girl was taken to a hospital for evaluation. The child, who had no past medical history, was transferred to another hospital for suspicion of appendicitis.

Her pain was initially in the periumbilical region and then extended to her right lower quadrant and back. She experienced nausea but did not vomit or have diarrhea or a fever. Two days prior to going to the hospital, she was seen by her pediatrician but was sent home. The girl was taken to the emergency room because her pain had worsened and she lost her appetite, the authors wrote.


During an exam, clinicians determined that her vital signs were normal and her labs were unremarkable. However, a noncontrast CT scan revealed a 2.7-cm, radiopaque, linear object in her terminal ileum. The girl denied swallowing any foreign objects.



*Arrow indicates where the orthodontic wire perforated the girl's terminal ileum adjacent to her appendix.*

The child was then admitted to the hospital, and a laparoscopy was scheduled for the next day. During the procedure, clinicians discovered that she had an inflamed and dilated appendix adjacent to the terminal ileum. They found that a green-gray metallic wire had punctured the terminal ileum in a "pinpoint fashion."

The team extracted the wire without the need for intestinal repair and removed her appendix. The girl was discharged the day after the procedure and needed no subsequent care, the authors wrote.



*The gray-black, semiflexible orthodontic wire.*

## Importance of cause

Appendicitis is one of the most common diseases in children, affecting approximately 70,000 children in the U.S. every year. However, pediatric cases of appendicitis caused by foreign bodies are rare.

Only 21 cases of appendicitis caused by foreign bodies were reported in 2020. During the past 80 years, there have only been 34 reported cases, and none of the foreign bodies were dental-related objects, according to the authors.

Though the symptoms of the condition were in line with the diagnosis, the root cause of appendicitis in this case is unique in that the irritator, an orthodontic wire, caused the inflammation. Prompt management is important because it decreases morbidity and prevents prolonged hospital stays, the authors wrote.

"While appendicitis is a common disease, foreign bodies should be considered when imaging shows a radiolucent object in the appendix," Sacks and colleagues concluded.

♥ [If you like this content, please share it with a colleague!](#)

Copyright © 2021 DrBicuspid.com

Last Updated np 6/4/2021 5:32:56 PM

## Forum Comments

1 comment so far ...

**6/7/2021 1:23:10 PM**

**S. Bornfeld**

I guess it's a good thing they didn't try an MRI first!

---

**Post your comment ...**

## Woman's mouth sensations return after prompt dental nerve repair

By Melissa Busch, DrBicuspid.com associate editor

May 12, 2021 – A woman in Japan can once again feel pain and temperature in her mouth thanks to the immediate repair of her alveolar nerve, which was damaged during jaw surgery. The case report was published on May 10 in the *Journal of Oral and Maxillofacial Surgery, Medicine, and Pathology*.

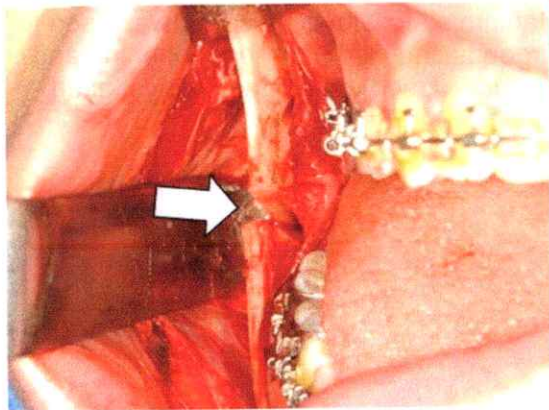
ADVERTISEMENT



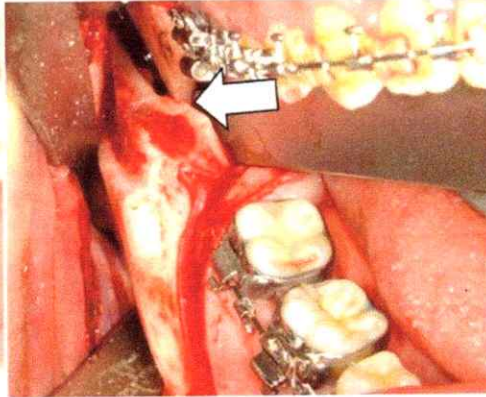
**IT'S ALL IN THE BOX**  
It's like having an entire IT team in the box. **ONE | TechCentral**  
[FIND OUT MORE](#)

Clinicians cut her inferior alveolar nerve, which supplies sensation to the lower teeth, while performing a bilateral sagittal split ramus osteotomy to align the woman's jaw. This is believed to be the first report to evaluate neurosensory disturbance after immediate repair of this severed dental nerve using a polyglycolic acid sheet and stellate ganglion block. The woman's mouth sensations were restored after 15 months, the authors wrote.

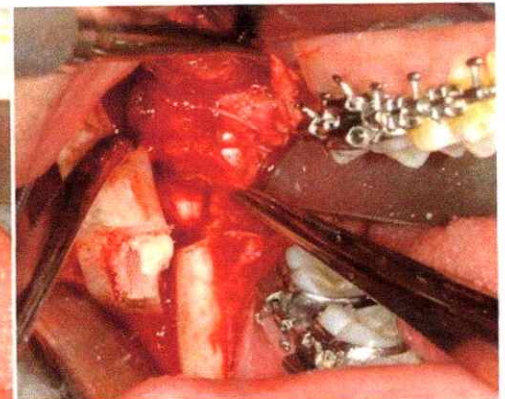
**A**



**B**



**C**



*Intraoperative view of the patient's mouth. (A, B) The white arrow points to the severed inferior alveolar nerve (IAN). (C) The nerve was removed from the mandibular foramen. All images courtesy of Kasahara et al. Licensed under [CC BY-NC 4.0](#).*

"The paresthesia in right sensory domain of the IAN [inferior alveolar nerve] had been restored to that before the surgery," wrote the group, led by Dr. Kiyohiro Kasahara of the department of oral pathobiological science and surgery at Tokyo Dental College.

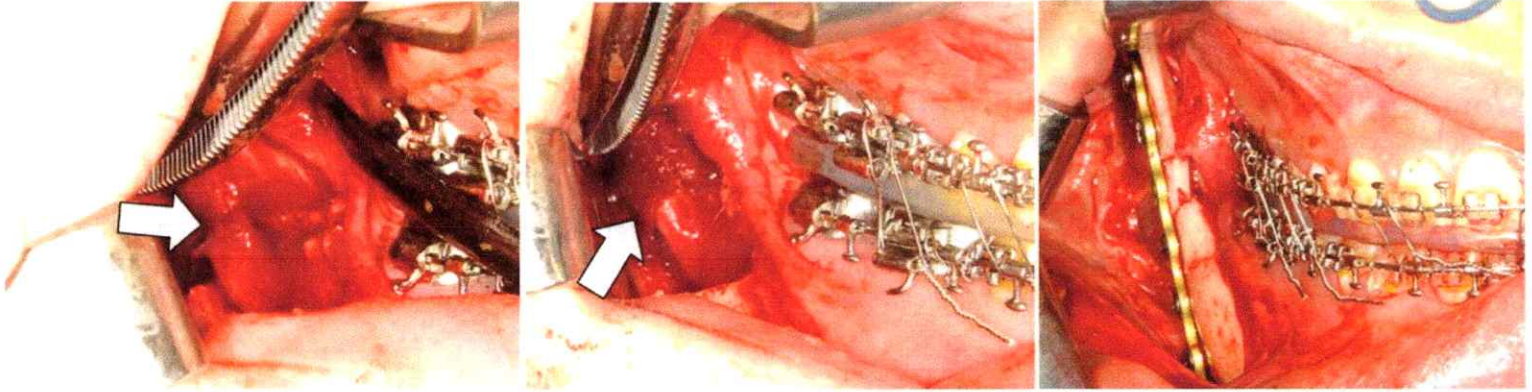
A bilateral sagittal split osteotomy is a type of jaw surgery in which the lower jaw is moved forward or backward to improve teeth alignment. Fractures, excessive bleeding, and damage to the inferior alveolar nerve or lingual nerve are known risks associated with the procedure. Though nerve damage is a well-documented complication and medical professionals agree early nerve repair results in better outcomes, there is little evidence describing outcomes following immediate repair.

In August 2019, a woman was given general anesthesia and underwent a bilateral sagittal split osteotomy to treat her protruding lower jaw. During the procedure, surgeons confirmed that her inferior alveolar nerve was severed completely. They reorganized her treatment plan so the surgeons could repair the nerve immediately, the authors wrote.

A

B

C



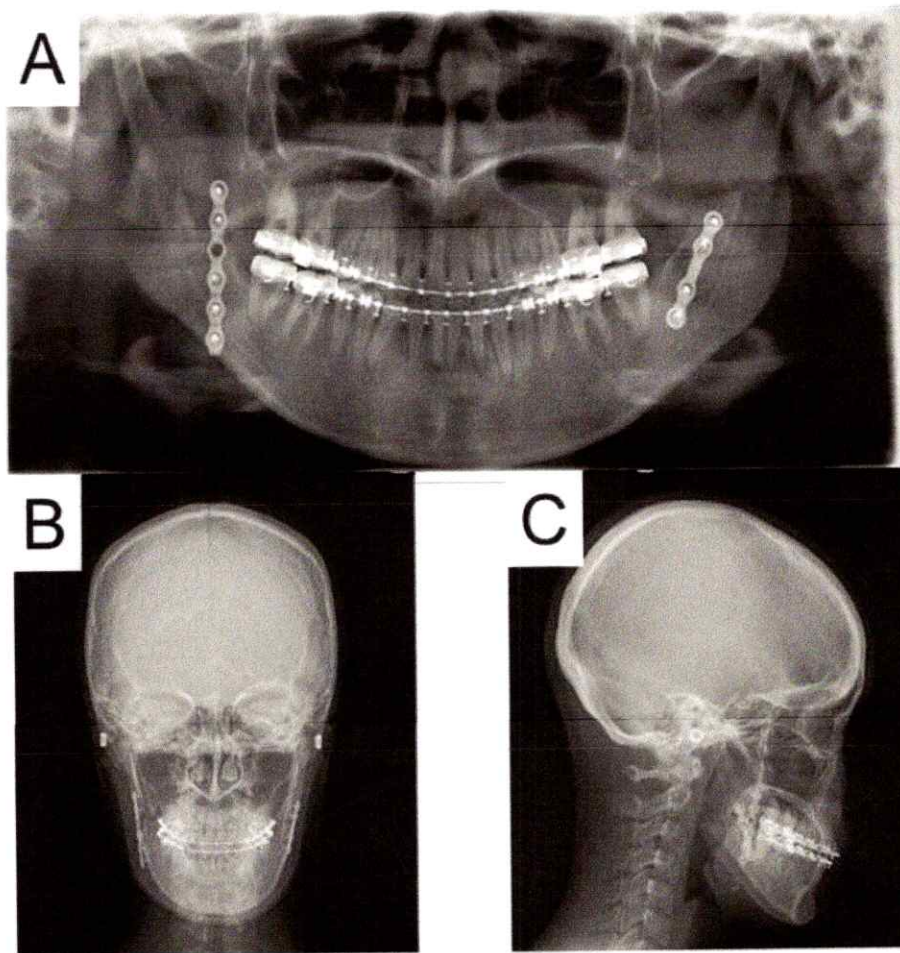
*Intraoperative view after nerve repair. (A) The white arrow points to the three 7-0 polyglycolic acid sutures. (B) The white arrow points to the polyglycolic acid mesh sheet used to protect the repaired nerve. (C) A monocortical titanium plate with five screws was used for the repair.*

First, supersonic wave instruments were used to remove the split osteotomy stump of the distal segment of the right side of the jaw. This provided a better view of the distal inferior alveolar nerve, which had been ripped from the lower jaw foramen, they wrote.

Next, clinicians sutured the nerve stump and removed the right distal part of the buccal cortical bone to get a better view of the proximal side of the nerve. Because moving the fixed jaw could cause the nerve reconnection to fail, they repaired the nerve before performing the intermaxillary fixation. They stitched up the epineurium every 120° using three polyglycolic acid sutures while using a magnifying glass. They protected the repaired portion with absorbable polyglycolic acid mesh sheet.

Finally, clinicians put back the removed distal cortical bone. A monocortical titanium plate with five screws was used to fix the right side, and a plate with four screws was used to fix the left side. Surgeons checked her mouth opening and occlusion after they removed the wires between her upper and lower jaws and then closed the wound. X-rays taken after the procedures showed no abnormalities.





*Postoperative radiographs of the patient showed no abnormalities.*

Throughout the procedures, the woman was injected with numbing agent 27 times to minimize pain. She was prescribed 6.6 mg of dexamethasone sodium phosphate for 14 days and vitamin B12 for six months after surgery, the authors wrote.

Immediately after the surgeries, the woman's right dental nerve did not respond to pain or temperature. The perception of sensation was tested again at three months and at six months. She started feeling some sensation at six months and then continued to improve. Prompt treatment along with the use of the polyglycolic acid mesh sheet and stellate ganglion block aided in her recovery, the authors wrote.

"The sensations of pressure, pain, and temperature after one year and three months were restored to the preoperative level," Kasahara and colleagues wrote.

♥ [If you like this content, please share it with a colleague!](#)

Copyright © 2021 DrBicuspid.com

Last Updated np 5/11/2021 3:54:20 PM

### Forum Comments

[Post your comment ...](#)



## Dental impression material gets stuck in man's throat

By Melissa Busch, DrBicuspid.com associate editor

July 28, 2021 -- A 71-year-old man ingested a nearly 2-inch piece of dental material that ended up stuck in the lower part of his throat while having impressions taken at a Kentucky clinic. The clinical report was published in the *Journal of Prosthetic Dentistry*.



Clinicians could not detect the lodged impression material radiologically, so an otolaryngologist planned to remove the object surgically. But while preparing for the procedure, the man bent down to untie his shoes and coughed, which removed the stuck material.

Though the man avoided surgery, this case highlights the importance of taking special care when performing impressions on patients, the authors wrote. This is especially true for older patients and those with dysphagia and weakened gag reflexes.

"Given the potential for morbidity and mortality that may arise from such misadventures, all dental practitioners should implement preventive strategies to reduce the incidence of such events," wrote the authors, led by Dr. Fonda Robinson from the Ohio State University College of Dentistry (*J Prosthet Dent*, July 17, 2021).

### From dental clinic to emergency room

The man visited the University of Kentucky College of Dentistry dental clinic to get impressions of his upper and lower teeth for the fabrication of removable dentures. In addition to having high blood pressure, the man experienced an occlusive cerebrovascular attack five years earlier that resulted in him experiencing some dysphagia, according to the report.

An operator adapted a green stick modeling plastic impression compound to the outside of a maxillary tray, then placed relief holes. Then, the operator followed the manufacturer's instructions to paint adhesive onto the tray surface and borders.

The tray was placed in the patient's mouth over his maxillary edentulous soft tissues, and the material was allowed to polymerize for about five minutes, the authors wrote. As the tray was being removed from his mouth, the patient gagged a little.

At that time, the operator saw a thin strand of polymerized impression material extending from the back of the tray, which looked like it had been separated or torn from additional material that could not be seen. The patient coughed several more times. He felt something at the base of his throat that he could not dislodge or swallow, but he could otherwise swallow and speak and showed no signs of respiratory distress.

Immediately, the man went to the emergency department, where an otolaryngologist saw the impression material in the man's hypopharynx. After several unsuccessful attempts by emergency department staff members to help him dislodge the material, the clinician ordered a lateral neck x-ray. The radiologists reported no significant radiographic findings, so the otolaryngologist planned to remove the object surgically, they wrote.

As the patient prepared for the operating room, he bent down to untie his shoes. He then forcibly coughed and dislodged the impression material on his own.

The otolaryngologist examined the man and confirmed that the material was no longer present in his hypopharynx. Fortunately, the man experienced no other related complications.

### Prepare for everything

Upon examination, a prosthodontist determined the object in the patient's throat was consistent with polyvinyl siloxane impression material, according to the report. Based on the look of the recovered material, the object likely was stuck just dorsal to the trachea in the hypopharynx.

The material showed several anatomic parts, including the bilateral piriform recesses. The interarytenoid notch, which is a congenital variation of the larynx, could also be seen on the impression material, they wrote.

Cases like this one of aspiration or ingestion of foreign objects are well-documented risks in dentistry, the authors wrote. Clinicians and their teams must be prepared to manage these types of emergencies.

"The dental team must use risk reduction strategies by identifying and reducing risk factors whenever possible," Robinson and colleagues wrote.

♥ [If you like this content, please share it with a colleague!](#)

Copyright © 2021 DrBicuspid.com

Last Updated ka 7/27/2021 4:48:38 PM

### Forum Comments

1 comment so far ...

**7/28/2021 9:10:20 AM**

**MWDavisDDS**

A few years ago, an attorney brought a similar case to my desk. The patient swallowed substantial quantities of impression material w/ a final PVS impression. The final impression was delivered by an inexperienced chairside assistant (in violation to state admin codes, as only the licensed dentist may lawfully take final impressions).

The patient developed an obstructive bowel. Surgery on his small intestine removed two oblong sections of set blue-colored PVS, approx 3"x2" and 2"x1".

The case reached a quick settlement, & I was not required to deliver a deposition, or even a report of expert findings.

Michael W Davis, DDS  
Santa Fe, NM

---

**Post your comment ...**

## CBCT aids in retrieval of broken 1.3-cm needle from man's mouth

By Melissa Busch, DrBicuspid.com associate editor

July 21, 2021 -- Cone-beam computed tomography (CBCT) and two injection needles used as reference points assisted in the removal of a broken 1.3-cm suture needle from a man's buccal mucosa, according to a case report published recently in *Maxillofacial Plastic and Reconstructive Surgery*.

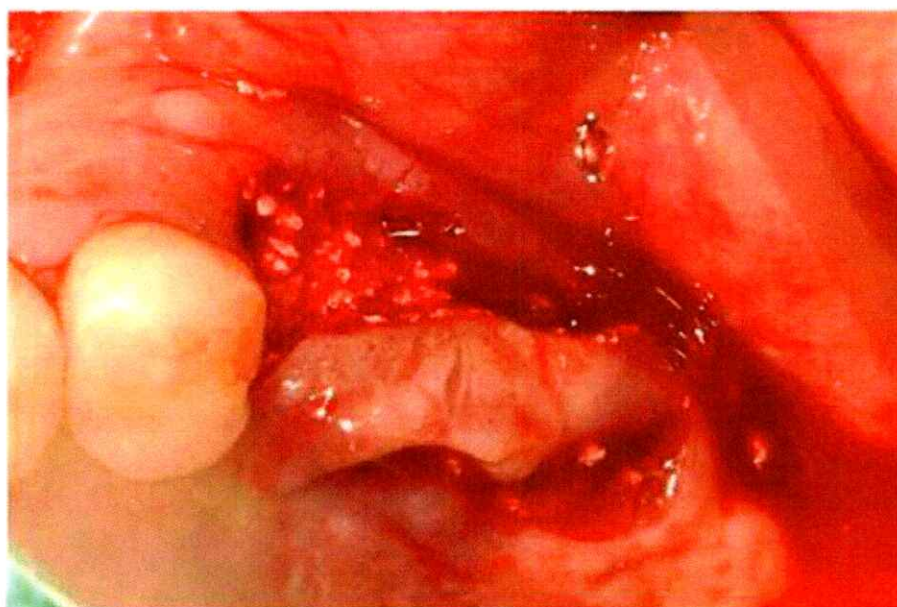ADVERTISEMENT



**SOLMETEX MAINTENANCE PROGRAM**  
Set your schedule and we do the rest.  
LAUNCHING JULY 1ST  
LEARN MORE

After a dentist accidentally cut the suture needle during the patient's procedure, the clinician tried to use a panoramic x-ray and CT to visualize and retrieve the needle but failed. The dentist was forced to refer the patient to oral and maxillofacial surgeons to have the needle removed, the authors wrote.

"This study reported a rare clinical case of removing the suture needle with the help of CBCT images," wrote the group, led by Dr. Suyun Seon from Kyung Hee University School of Dentistry in Seoul, South Korea (*Maxillofac Plast Reconstr Surg*, July 5, 2021).



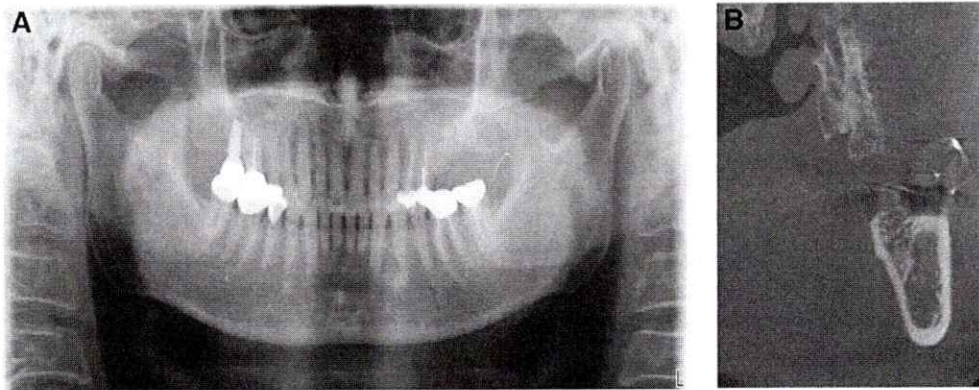
*Photo of the patient's mouth immediately after having explantation and flap surgeries at a dental clinic. All images courtesy of Seon et al. Licensed under [CC BY-NC-ND 4.0](https://creativecommons.org/licenses/by-nc-nd/4.0/).*

### Accidents happen

Breakage of suture needles is a rare but potentially serious occurrence in dentistry. Numerous factors, including limited visibility, difficult access, sudden patient movements, and mishandling of instruments by clinicians, can result in suture materials being lost, broken, or embedded in a patient's oral cavity.

When this occurs, it is vital that foreign objects be removed immediately to avoid serious complications, including massive bleeding and nerve injuries. Imaging helps in the retrieval of foreign bodies, but some imaging technologies

work better than others depending on the object and where it is located, according to the authors.



(A) Panoramic radiograph reveals needle fragment located at the anterior ramus of the left mandible. (B) A CBCT image of the lost needle, with two injection needles used as reference points.

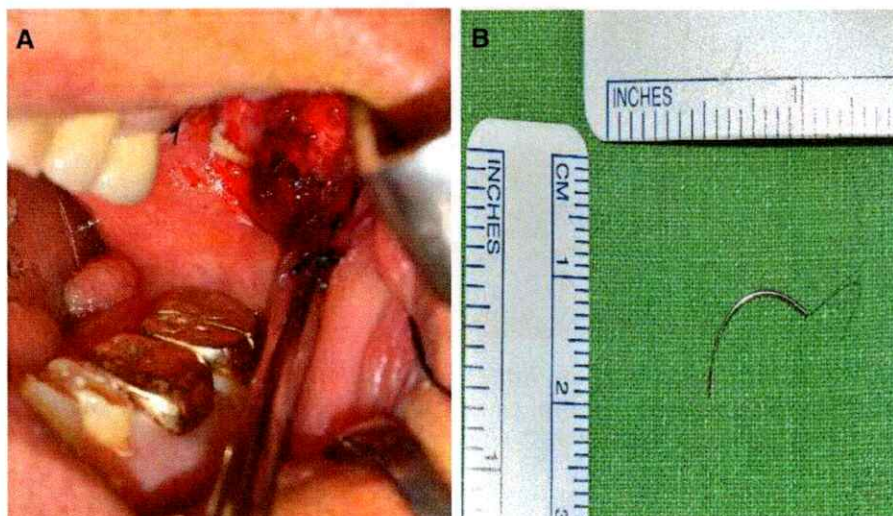In this case, the man's dentist referred him to the maxillofacial and oral surgery department to have a suture needle removed from his left buccal mucosa. The needle was supposed to be tied with nylon, but the dentist cut it while performing explantation and local flap surgeries due to the man's chronic peri-implantitis, they wrote.

When he arrived at the surgery department, the man had sharp pain at his surgical site, but it did not affect his ability to open his mouth. An x-ray confirmed that the suture needle remained in his left buccal space.

During an oral exam, a surgeon inserted two needles perpendicularly into the man's left buccal mucosa as reference points to better locate the lost suture needle. Then, the patient underwent a CBCT scan that revealed the broken needle was located above the injection needle and below the maxillary tuberosity, the authors wrote.

To remove the broken needle, surgeons opted to place the patient under local anesthesia and conduct a surgical exploration. A vertical incision was made on the man's left buccal mucosa along the ramus, and dissecting scissors were used to make a blunt dissection. However, surgeons stopped the procedure because they couldn't see the needle, and the man was experiencing pain.

After consulting with the patient, they placed him under general anesthesia to remove the broken needle. A deep dissection was made and the 1.3-cm suture needle, as well as the nylon fragment that was attached to it, were retrieved. Then, the incision was closed.



(A) Photo of single needle fragment lodged in the buccal mucosa. (B) The retrieved suture needle.

After the retrieval, x-rays were taken, which confirmed that the broken needle had been removed completely. One week after the removal procedure, the stitches were removed. The patient was healing and experienced no complications.

Exact localizations and surgical approaches are necessary for removing foreign objects in the head and neck area. CT scans may not measure accurately the real position of a foreign object due to intraoperative traction and swelling, Seon and colleagues wrote.

"Therefore, other up-to-date radiographic devices can be sometimes advisable when CT scan images are not practical," they concluded.

♥ **If you like this content, please share it with a colleague!**

Copyright © 2021 DrBicuspid.com

Last Updated ka 7/20/2021 10:16:55 AM

## Forum Comments

**Post your comment ...**



## Use of dental gag causes cardiac arrest in toddler

By Melissa Busch, DrBicuspid.com associate editor

April 9, 2021 -- A 5-year-old boy under general anesthesia for oral surgery went into serious cardiac arrest, triggered by his mouth being propped open with a dental gag, according to a case report published on March 26 in the *Journal of Oral and Maxillofacial Surgery*.

ADVERTISEMENT



Excessive mouth opening with a dental gag triggered the reflex of the trigeminal and vagal nerves, immediately causing a rare case of asystole. The boy made a full recovery, the authors wrote.

"The trigeminovagal reflex was most likely elicited by stretching the masticatory muscles and triggering an afferent response of the mandibular branch of trigeminal nerve," wrote the group, led by Dr. Hiroshi Hoshijima, PhD, an assistant professor at the Tohoku University Graduate School of Dentistry in Sendai, Japan.

### Rare but serious reflex

The trigeminal nerve is a complex cranial nerve that controls sensation in the face and motor functions, including chewing. When this nerve is stimulated, it triggers the trigeminovagal reflex, causing the sudden onset of bradycardia, hypotension, and cardiac arrest.

The trigeminovagal reflex is rare, occurring in about 2% of maxillofacial surgeries. It is defined as a decrease in heart rate and drop in arterial blood pressure of at least 20% compared to blood pressure prior to trigeminal nerve stimulation.

The use of lighter anesthesia during surgery is one risk factor for triggering the reflex. Younger patients are also at a higher risk, the authors noted.

### Multiple attempts to complete surgery

In the documented case, a healthy boy was at the dentist to have maxillary supernumerary teeth extracted. After tracheal intubation, anesthesia was induced with sevoflurane (8%), nitrous oxide (4 L/min), and oxygen (2 L/min). Anesthesia was then maintained with sevoflurane (1%-1.5%), air (2 L/min), oxygen (1 L/min), and remifentanyl (0.2-0.3 µg/kg/min).

The clinicians opened the boy's mouth with a dental mouth gag at the beginning of the procedure and an electrocardiogram (ECG) showed asystole for 20 seconds. They prepared to administer chest compressions and use a defibrillator when the boy's heart rate spontaneously returned to baseline within 60 seconds.

After observing the patient for a few minutes, the dental team restarted the procedure and reopened the boy's mouth with the gag. The patient's heart rate suddenly decreased from 100 beats per minute (bpm) to 70 bpm when the interincisal distance of his mouth opening surpassed approximately 40 mm. His heart rate spontaneously returned to baseline within 15 seconds. These events occurred one more time, but his heart rate returned to baseline within one minute.

Fortunately, the surgery was completed without complications. The boy experienced no breathing or neurological problems, and he was discharged two hours after he woke up from the anesthesia, according to the authors.

Clinicians should be mindful of the possibility of triggering the trigeminovagal reflex when performing dental procedures that require excessive mouth opening, they wrote.

"This maneuver should be carefully performed because of the rare possibility of severe bradycardia or cardiac arrest, particularly under general anesthesia," Hoshijima and colleagues concluded.

♥ **If you like this content, please share it with a colleague!**

Copyright © 2021 DrBicuspid.com

Last Updated on 4/8/2021 1:50:16 PM

## Forum Comments

**Post your comment ...**